

# Practice for speed and proficiency in Cytology Exams using the new RCPA digital cytology eCases and Sectra

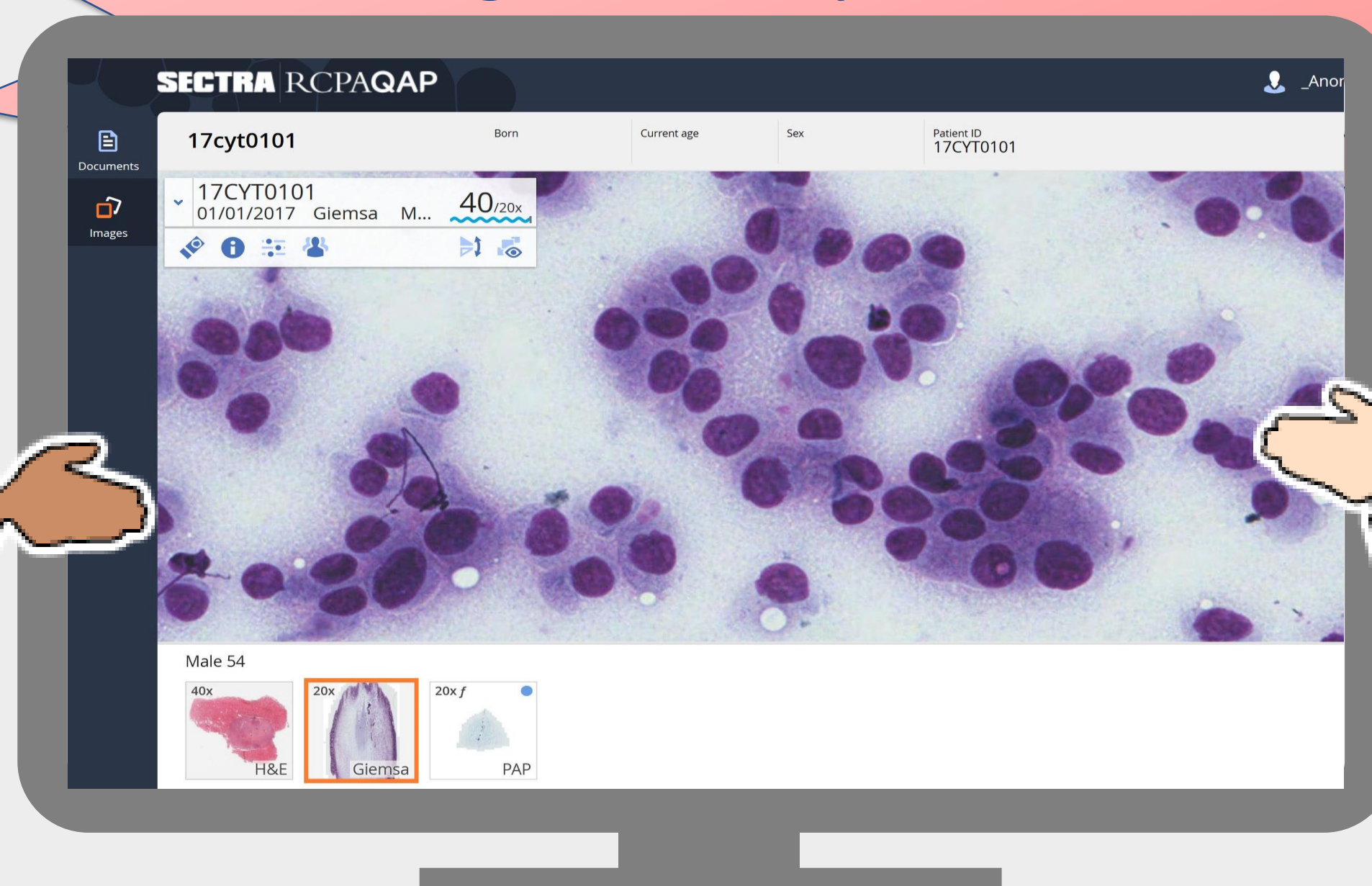
Amanda and Simone show you how.....

Amanda Charlton, Department of Histopathology, LabPlus, Auckland District Health Board, Auckland, NZ

Simone L Van Es, Department of Pathology, School of Medical Sciences, UNSW, Sydney, NSW, Australia.

## Prepare for the planned transition

to a digital cytology exam using Sectra platform



Where can we find practice cytology slides?

How do I make digital practice sets for the trainees?

Trainees

Supervisors

1 Screening and reaching a diagnosis using digital cytology is slower than glass slides.<sup>1</sup> Proficiency and speed comes with practice.<sup>1</sup>

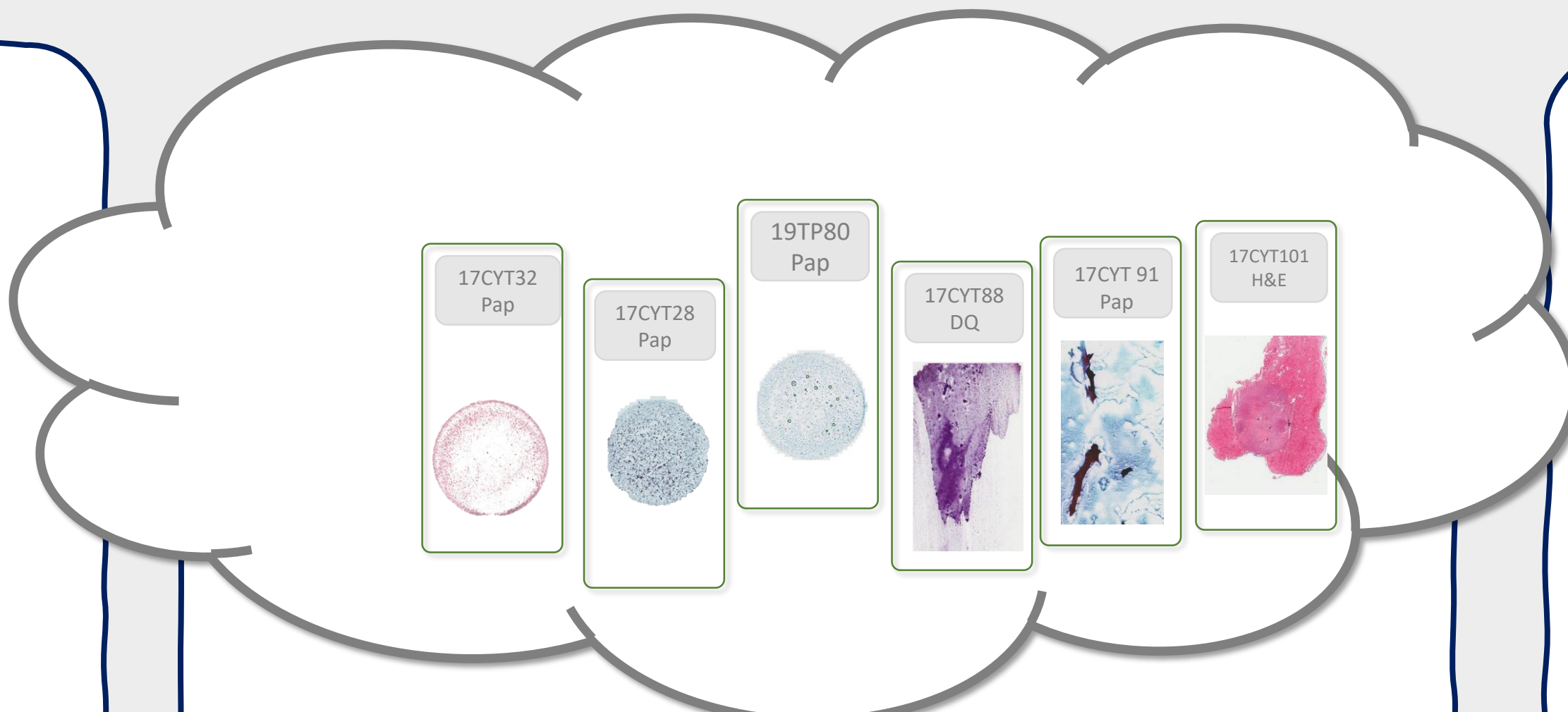
2 Practice tests, spaced recall and teaching others are 3 highly effective learning strategies.<sup>2</sup> Become proficient with Sectra.

3 Supervisors need to know how to make and share practice sets of digital cytology slides.



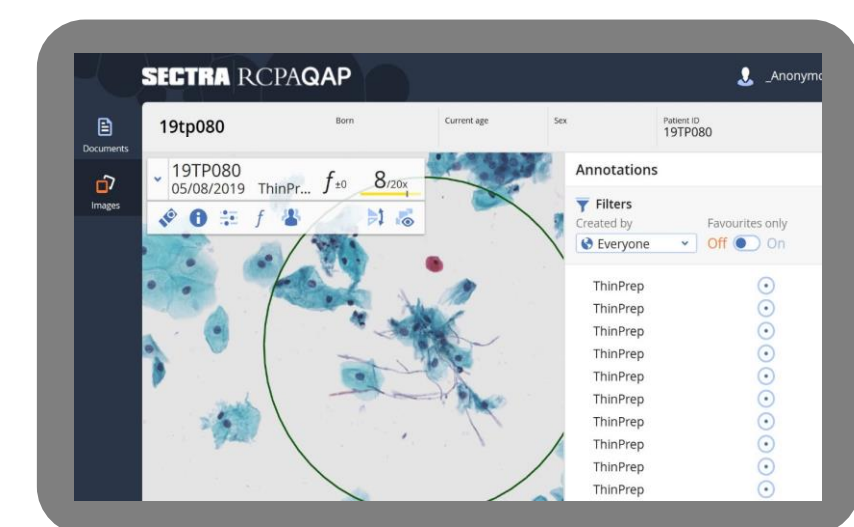
RCPA eCases

4 Enter the cytology slide library through the DOOR of the RCPA website. [Library/ecases/anatomical\\_pathology/cytology](http://Library/ecases/anatomical_pathology/cytology)



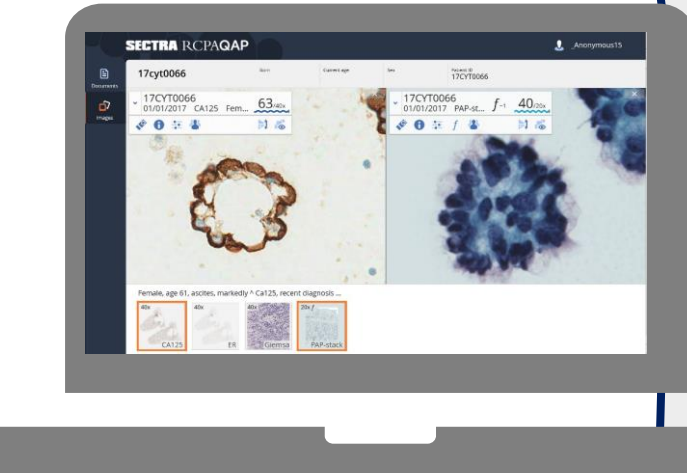
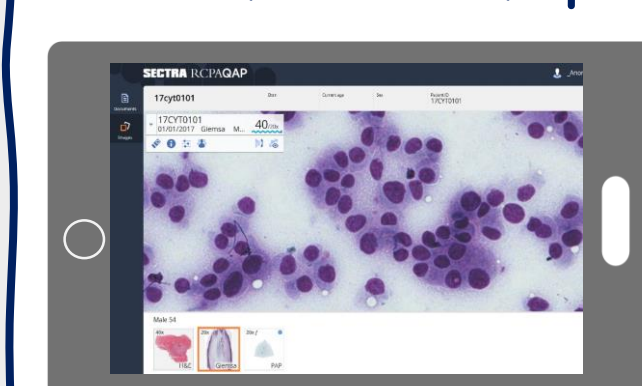5 There are >200 digital cytology cases including liquid based gynae, FNA, fluids and cell blocks with IHC.

Annotated and z-stack

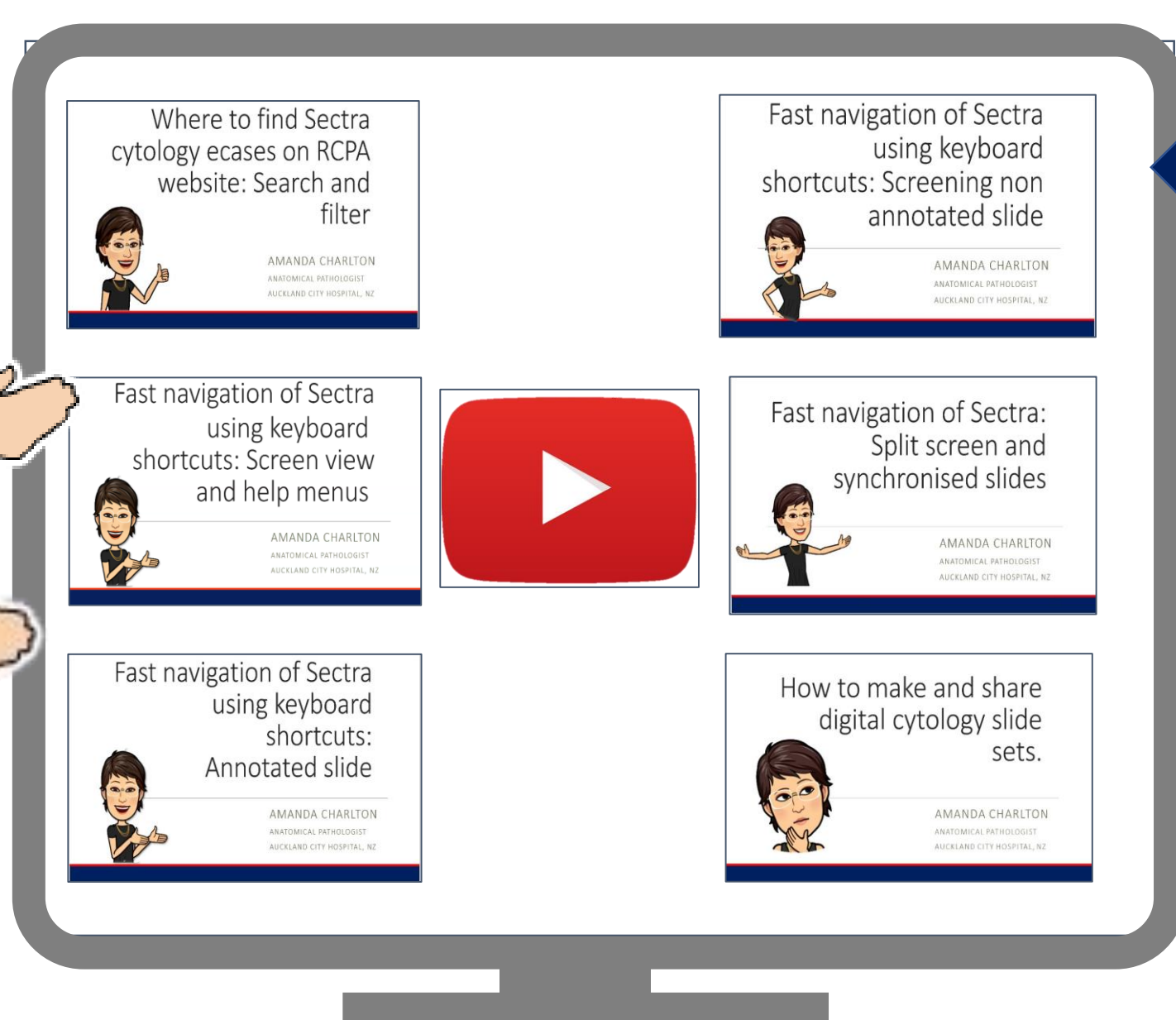

Compare slides

Phone, tablet, ipad



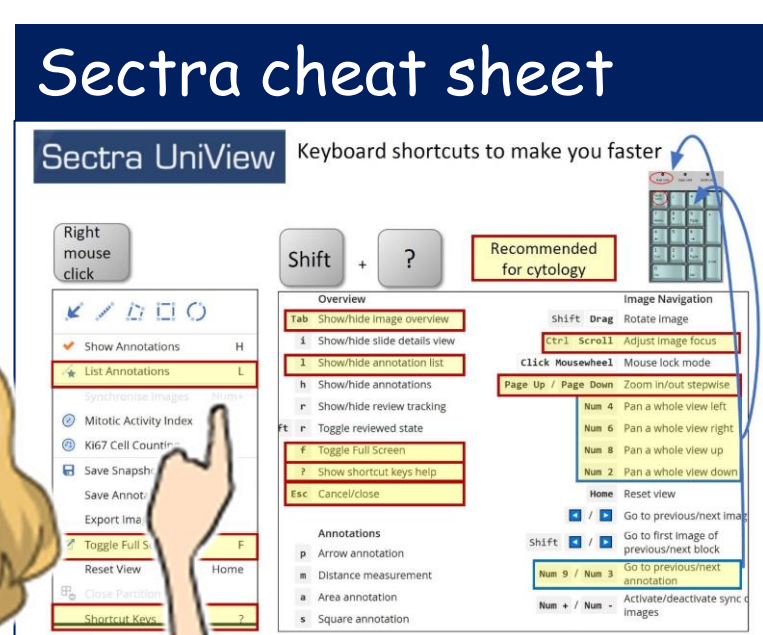
6 View and share the slides on any internet connected device. Sectra is cloud based, no software is needed.



videos

7 In this series of 6 short [videos](#), I show you....

- Where to find Sectra cytology slides
- Fast navigation shortcuts
- How to make and share practice slide sets.



8 Click the links to play the videos, do the test sets, and download a shortcut [cheat sheet](#),

test set

Test set
Case 1. 21y female. Cervical sample. 18TP080 <b>Diagnosis</b>
Case 2. 17CYT0101 54y male. Thyroid lump <b>Diagnosis</b>
Case 3. 17CYT066 61y female. Ascites, ovarian mass. <b>Diagnosis</b>

Answer set
Case 1. 18TP080 <b>Diagnosis</b> NEGATIVE FOR INTRAEPITHELIAL LESION C REACTIVE CHANGE. <a href="#">Discussion</a>
Case 2. 17CYT0101 <b>Diagnosis</b> Papillary thyroid carcinoma <a href="#">Discussion</a>
Case 3. 17CYT066 <b>Diagnosis</b> Metastatic ovarian carcinoma <a href="#">Discussion</a>

9 An example online [test set](#). With a separate [answer set](#).

1. Van Es SL. Digital pathology: semper ad meliora. Pathology. 2019 Jan;51(1):1-10.

2. Dunlosky J, Rawson KA, Marsh EJ, Nathan MJ, Willingham DT. Improving students' learning with effective learning techniques. Psychological Science in the Public Interest. 2013 Jan;14(1):4-58.