Difficult decisions for invasive cervical tumours

Dr Diane Kenwright
University of Otago, Wellington
CCDHB

Difficult decisions in SCC

- Micro invasive vs in situ
- SCC with no clear evidence of invasion
- Mimics of invasion

Recognising microinvasion

CIN3 with features suggestive of impending or early stroma invasion. Extensive involvement of both surface epithelium and deep endocervical crypts (a, b). Expansion of the involved crypts with evidence of central comedo-type necrosis (c, d).

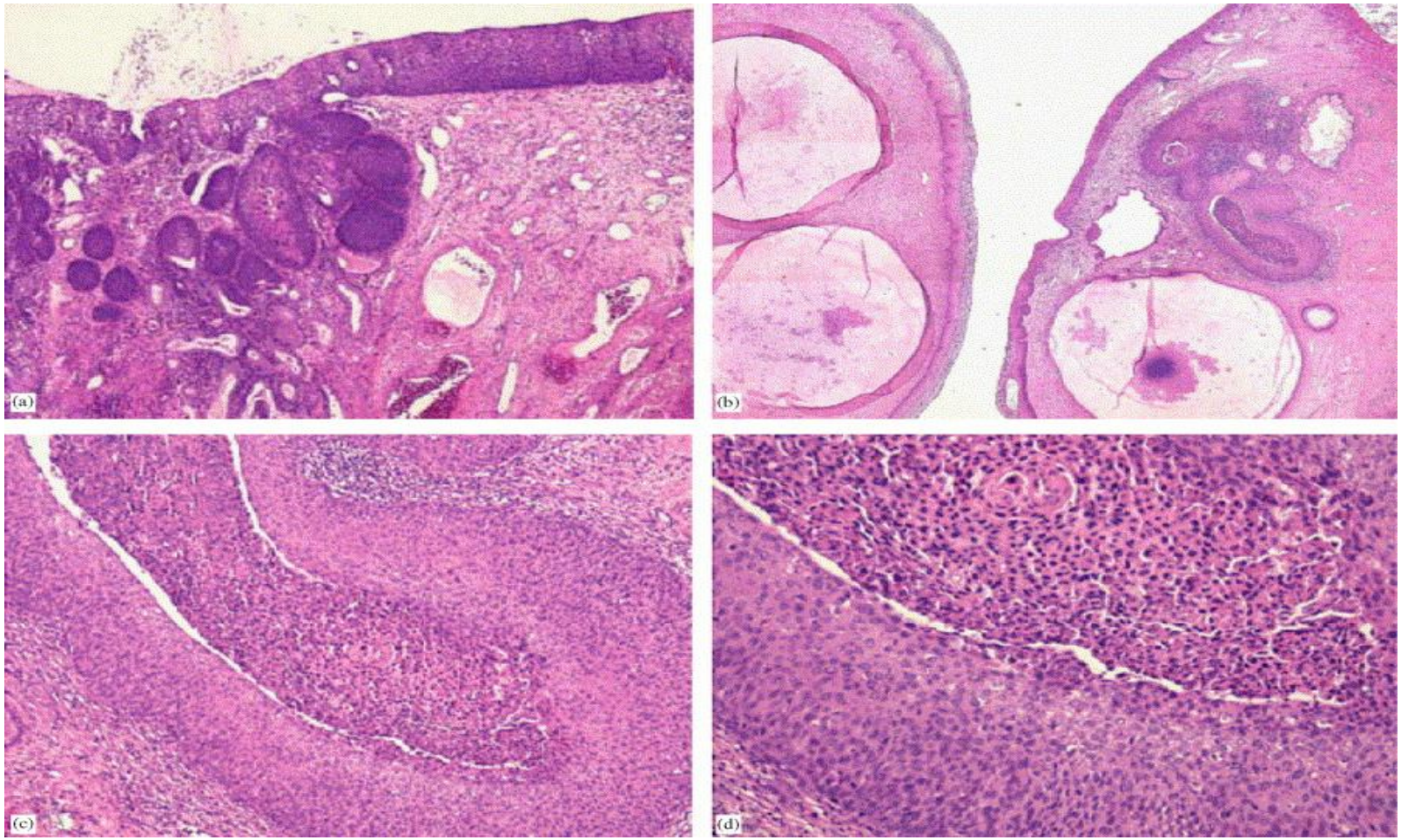

Current Diagnostic Pathology Volume 12, Issue 5 2006 364 - 393

CIN3 with focal squamous or eosinophilic maturation and evidence of very early stromal invasion

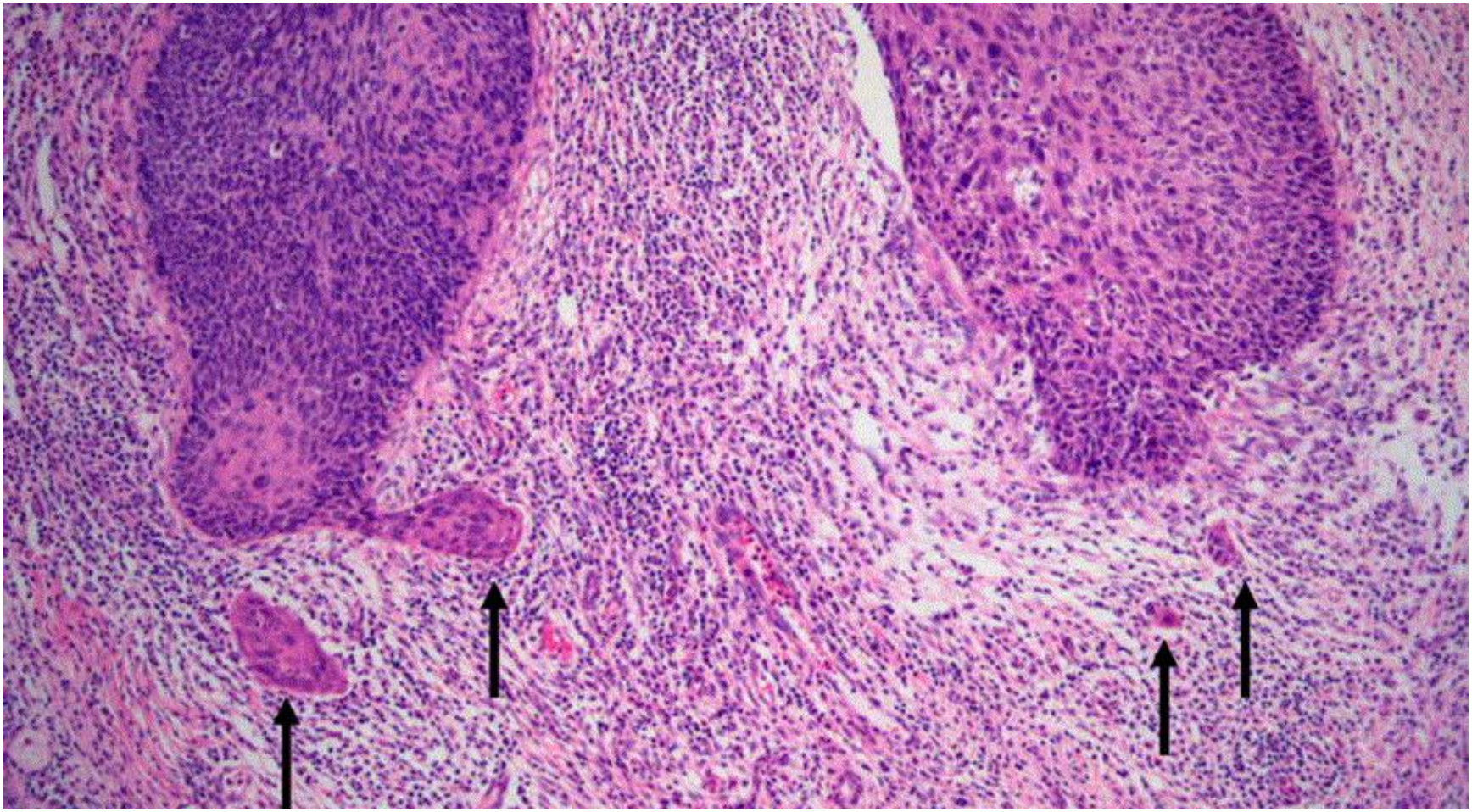

Deeper levels of section containing CIN3 with features of impending invasion often reveals foci of early microinvasion (arrows). Also notice inflammatory response.

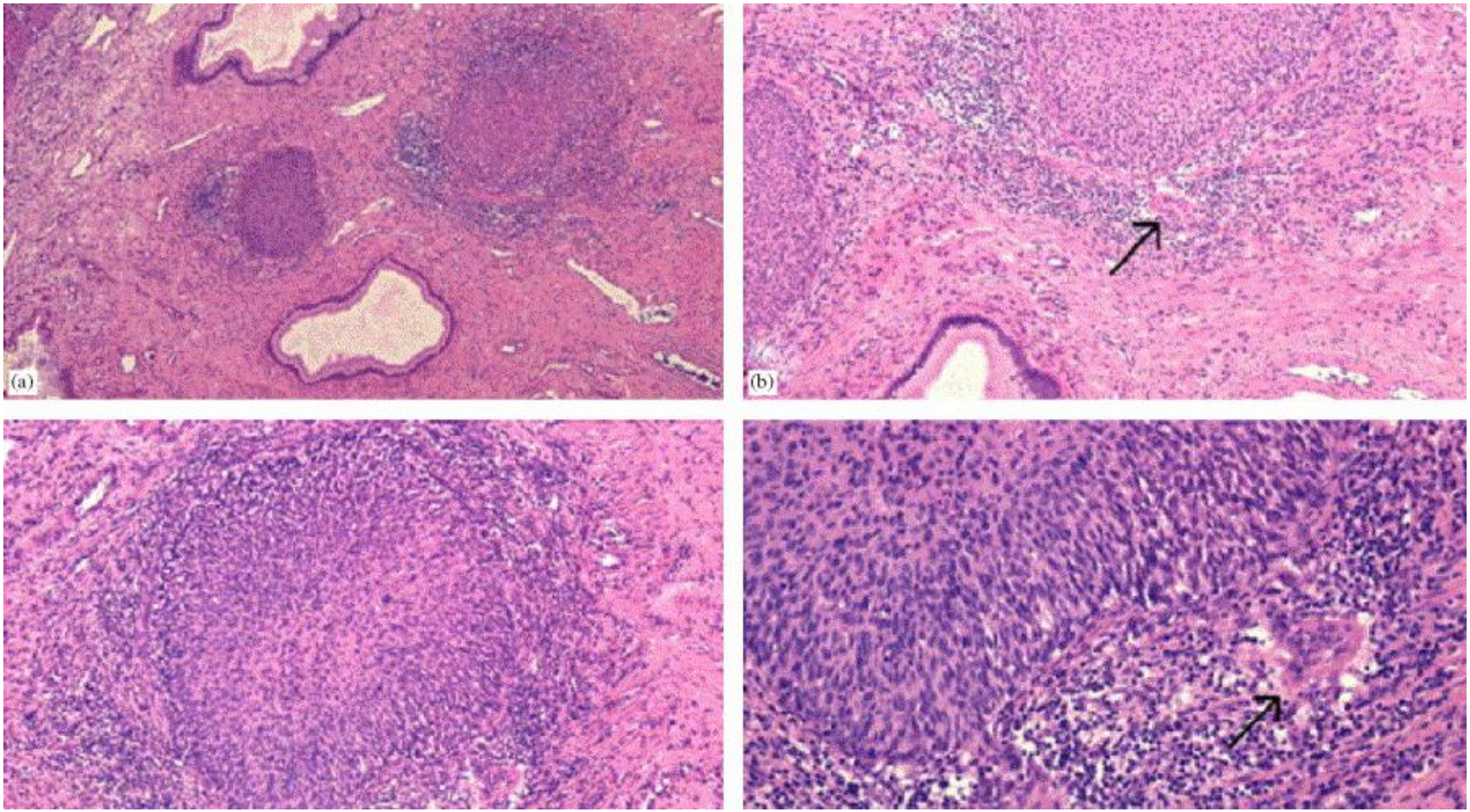

CIN3 with features of impending invasion showing foci of early stromal invasion. The invasive foci consist of irregular tongues or buds of more differentiated epithelial cells, with intense cytoplasmic eosinophilia and loss of the normal palisade-like arrangement of the basal layer (c and d).

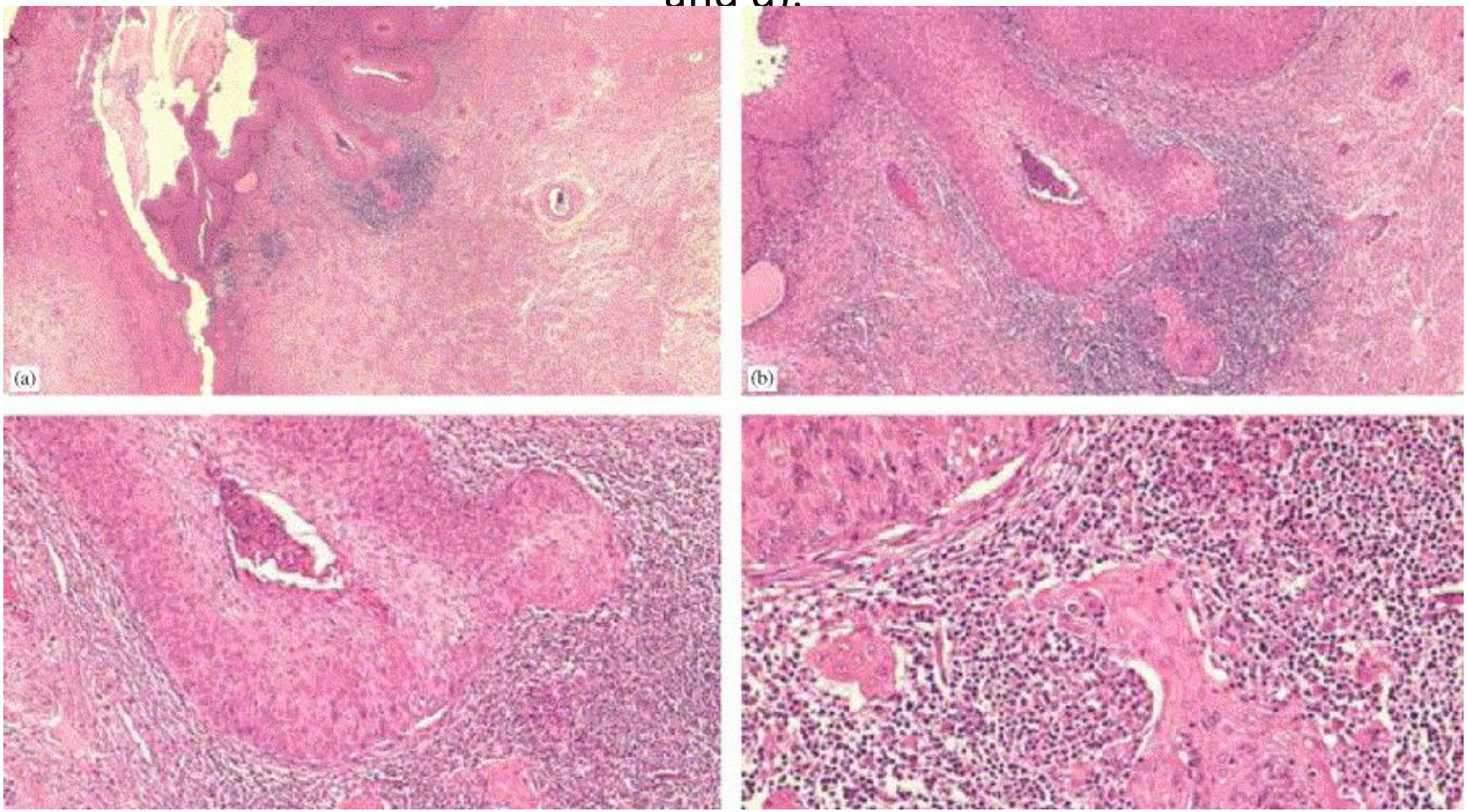

Cervical squamous carcinomas with no clear evidence of invasion

- **CIN3-like invasive squamous carcinoma**
- similar to CIN3 occupying deep endocervical crypts with some irregularity and a back-to-back arrangement
- very prominent comedo-necrosis, quite obvious intra-lesional squamous maturation, and frequent peripheral bulging of what appear to be deep endocervical crypts.
- these nests are often seen in association with small tongues of invasion surrounded by stromal loosening and various degrees of inflammation.

CIN3-like invasive squamous carcinoma showing CIN-like lesion occupying deep endocervical crypts with some irregularity, back-to-back arrangement and very prominent comedo necrosis.

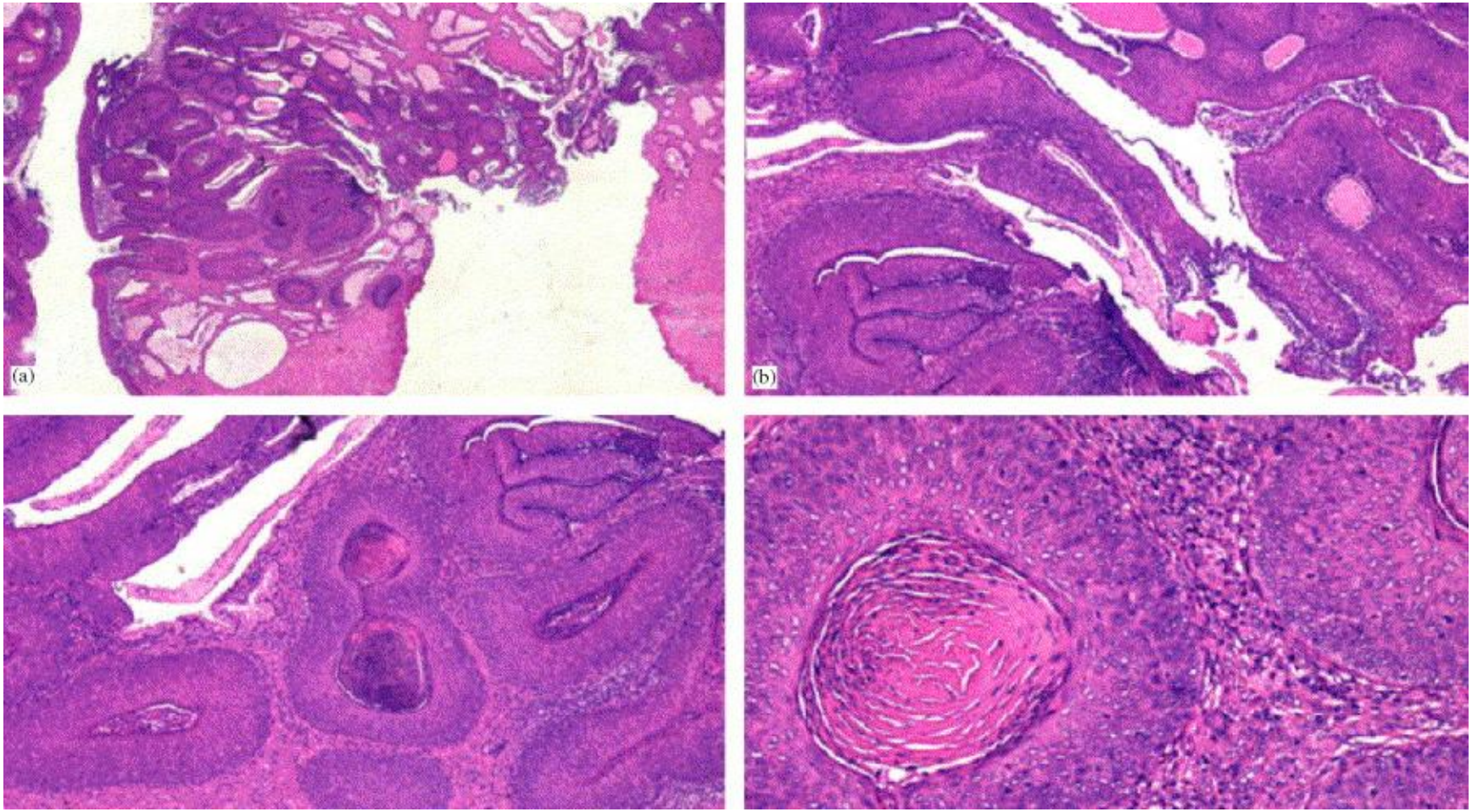

- **Papillary squamous (squamotransitional) cell carcinoma**
- This tumour is frequently mistaken for a squamous papilloma
- in a small biopsy, one may only see the papillary non-invasive component
- reminiscent of grade 1 or 2 papillary transitional cell carcinoma of urothelial origin
- be cautious in diagnosing squamous papilloma in postmenopausal women, especially if these lesions exhibit dysplasia.
- a diagnosis of papillary squamotransitional cell carcinoma should alert you to the possibility of more advanced disease, or deeper invasion, in the remaining cervix.

Papillary squamotransitional cell carcinoma of the uterine cervix. The original cervical biopsy (a and b) shows superficial non-invasive papillary component. The follow-up hysterectomy (c and d) reveals similarly non-invasive component (c) and an in situ convensional CIN3 areas (d).

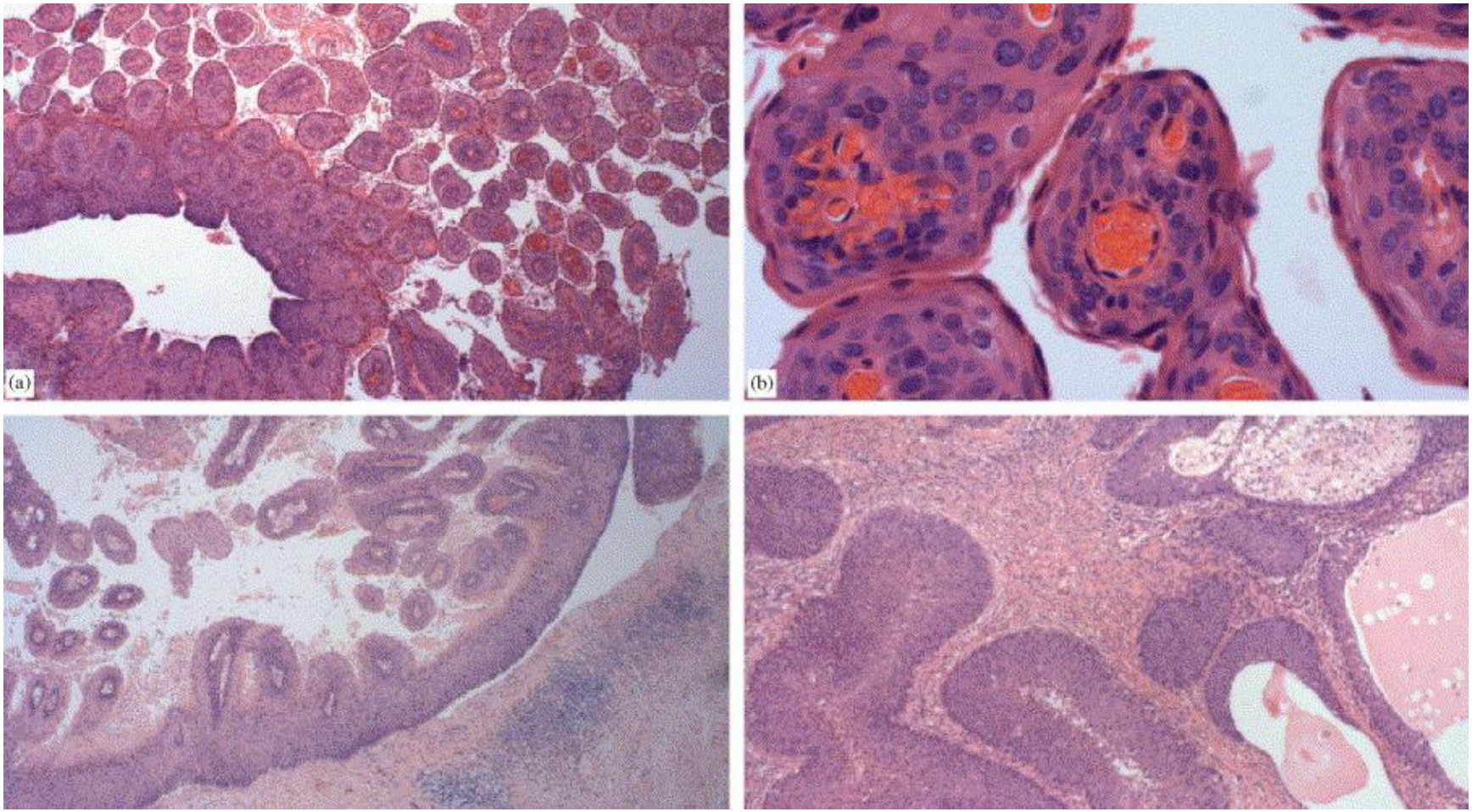

Mimics of invasive SCC

Stromal decidualization.

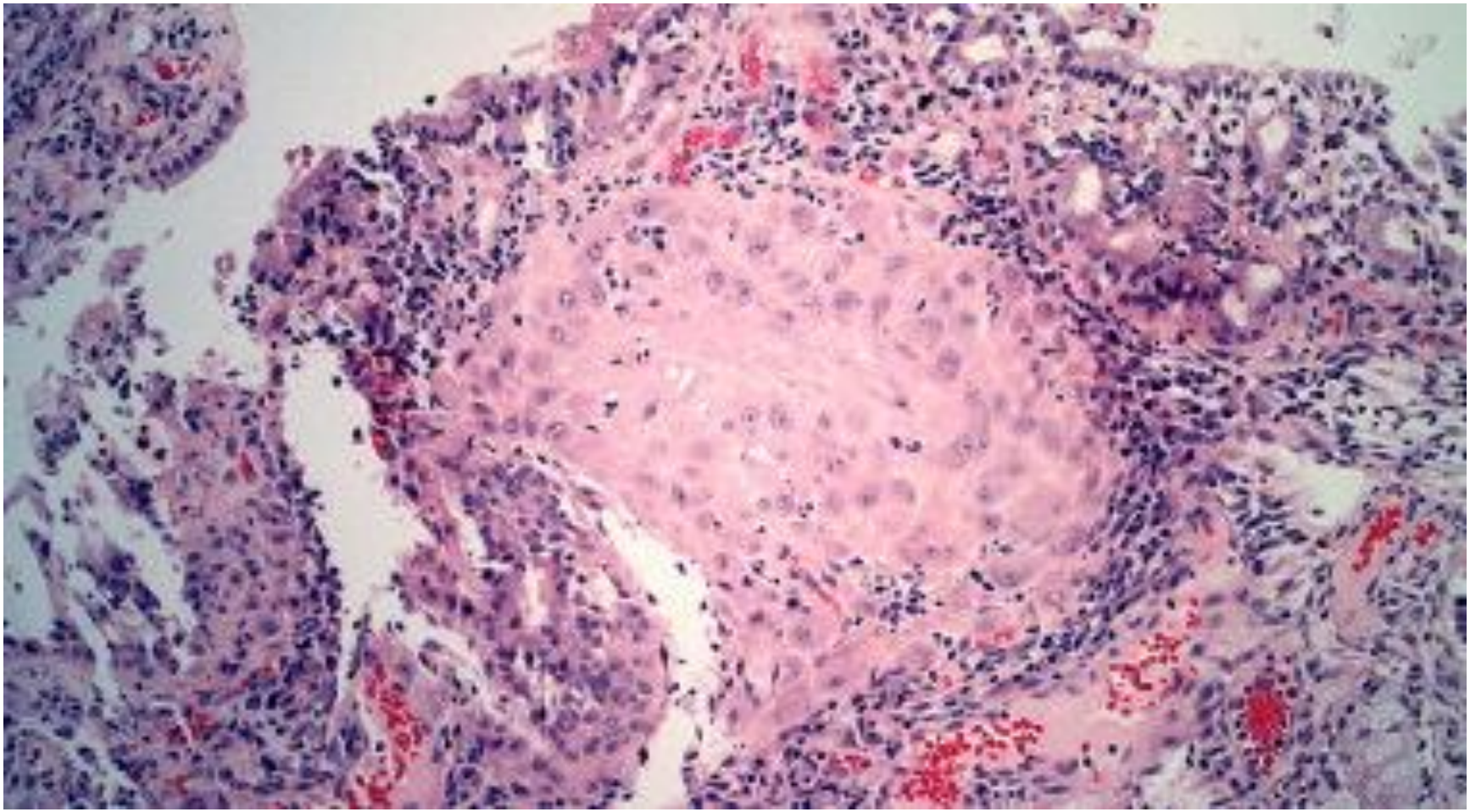

Difficult decisions in adenocarcinoma

- Microinvasive vs insitu
- Well differentiated (adenoma malignum)
- Benign lesions mimicking adenocarcinoma
- Cx vs endometrial adenocarcinoma

Morphological patterns of early invasive adeno carcinoma

1. An obvious small adenocarcinoma

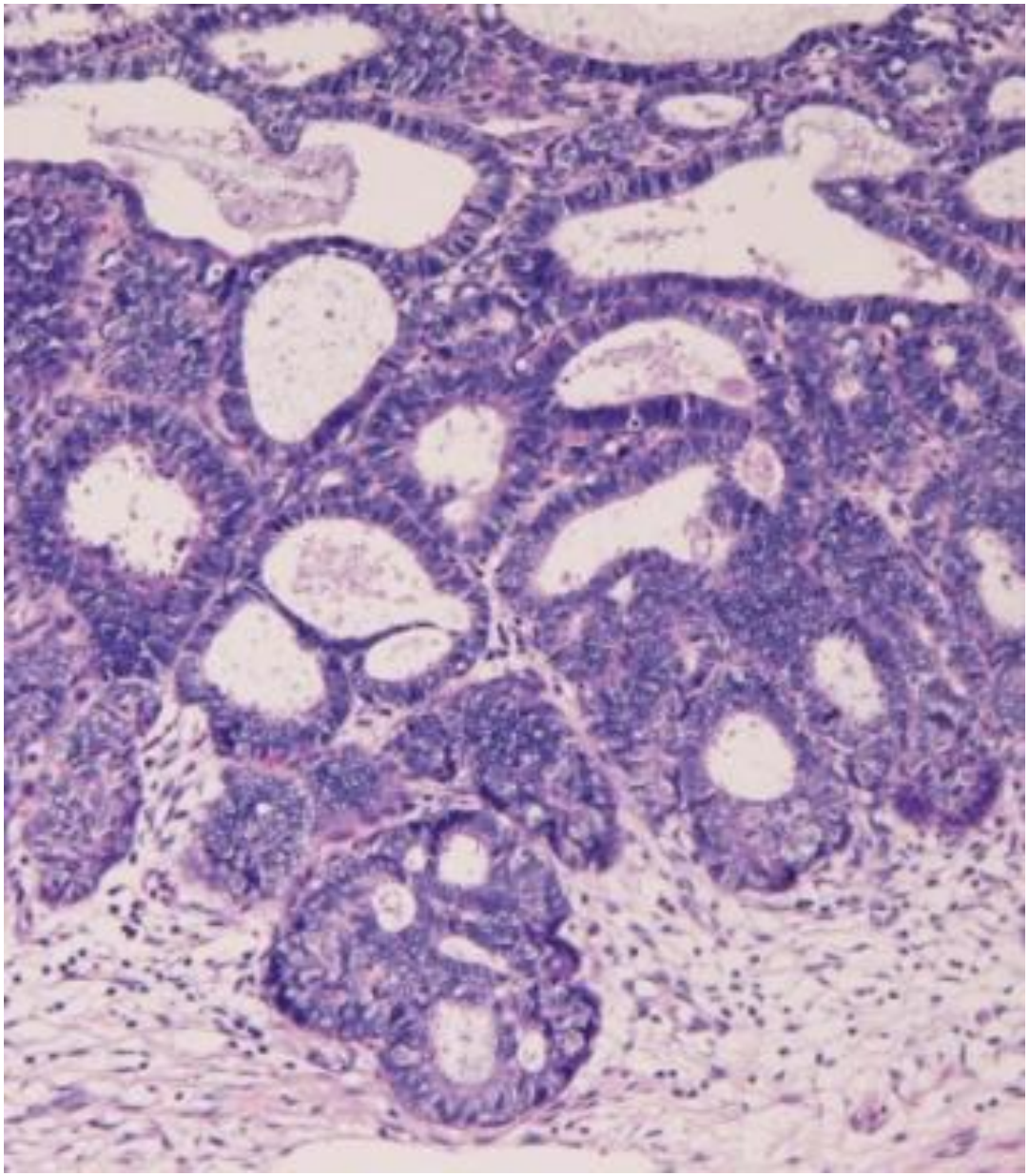

Morphological patterns of early invasive adeno carcinoma

- 2. Glandular pattern becomes complicated cribriform or solid, with a stromal reaction - oedema, desmoplasia, or an inflammatory infiltrate.

Early invasive adenocarcinoma

.A focally incomplete gland is associated with marked stromal reaction (A). Cribriform growth of malignant epithelium devoid of stroma within a single gland profile is associated with a prominent inflammatory response (B).

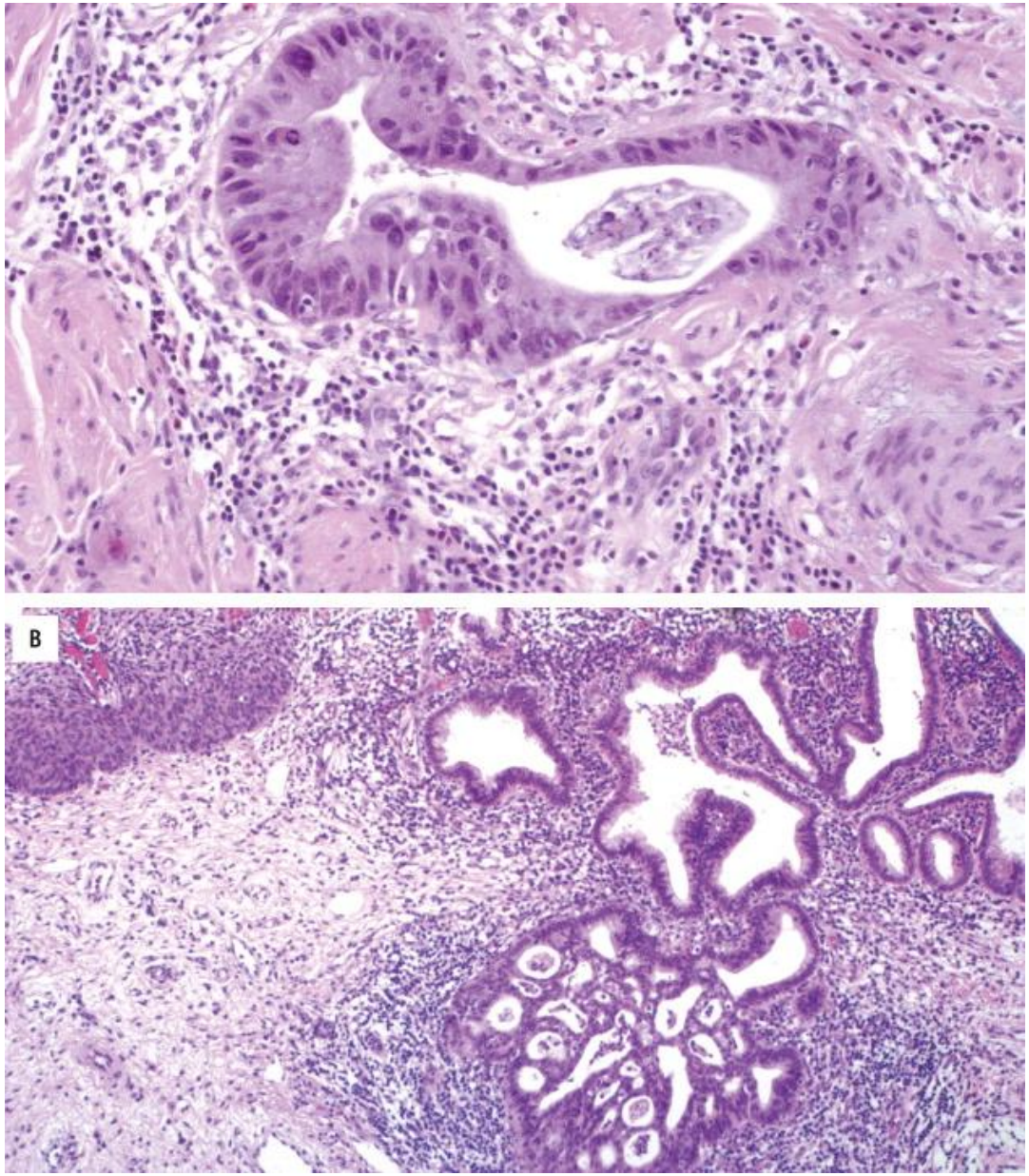

Features suggestive of early invasion are the presence of confluence and back-to-back arrangement of the involved glands and cribriform pattern

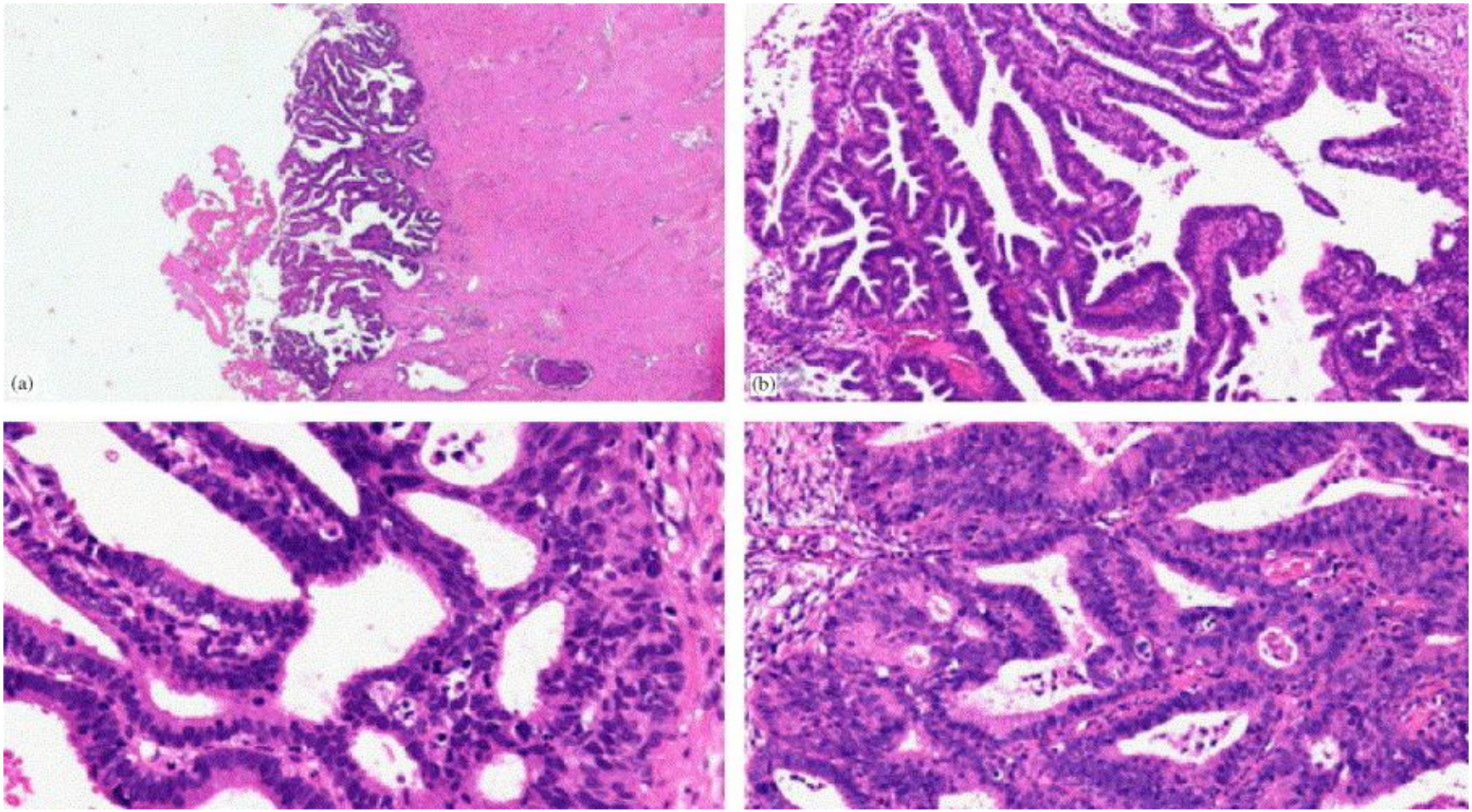

Confluent glandular pattern with cribriform areas.

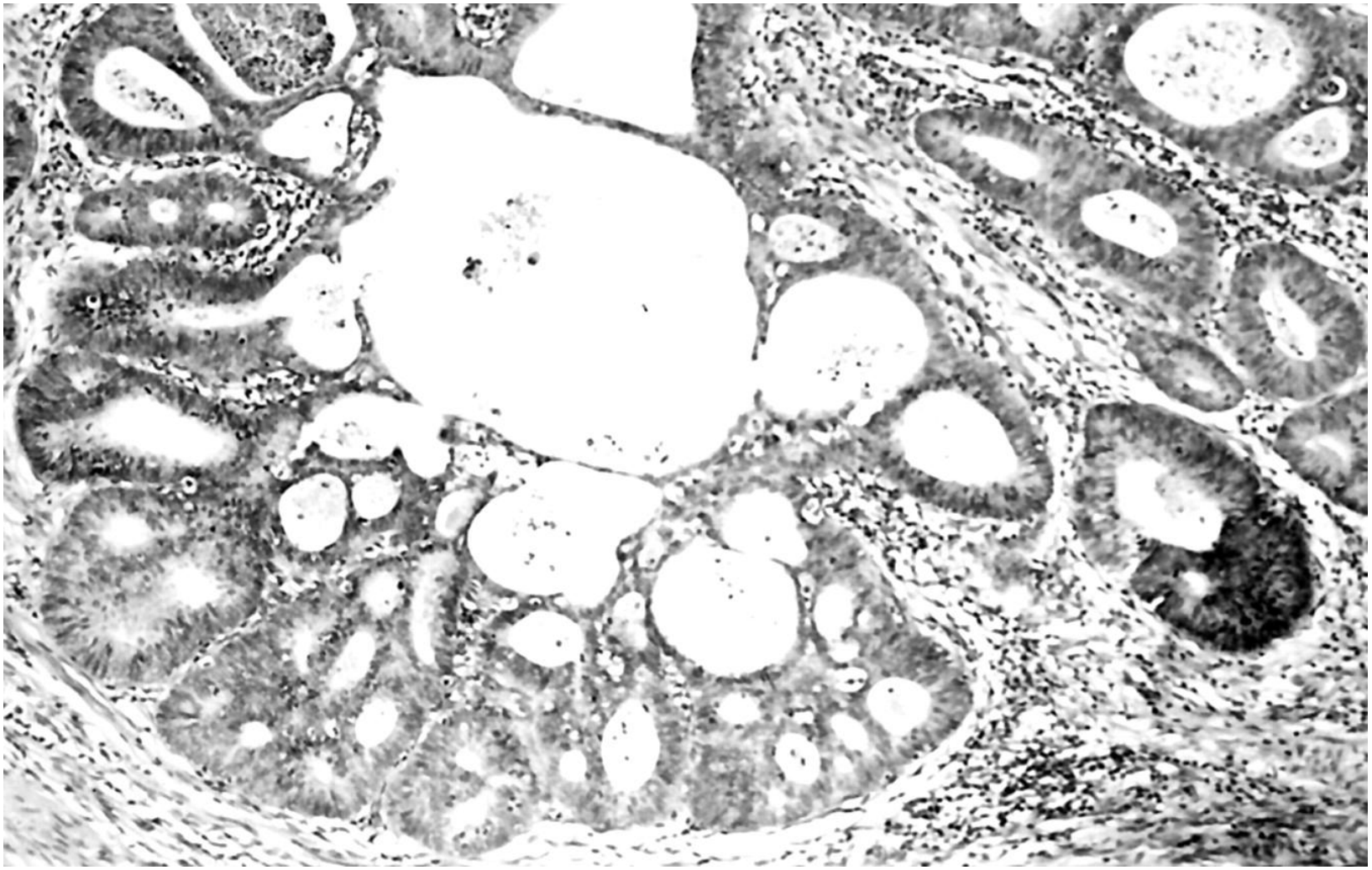

McCluggage W G J Clin Pathol 2003;56:164-173

Morphological patterns of early invasive adeno carcinoma

3. Small buds of cells often with a squamoid appearance arising from AIS

Amongst the features suggestive of stromal invasion is the presence of focal squamoid cytoplasmic change of the abnormal epithelium (arrows) resembling buds of early microinvasive squamous carcinoma. Also notice the florid inflammatory response.

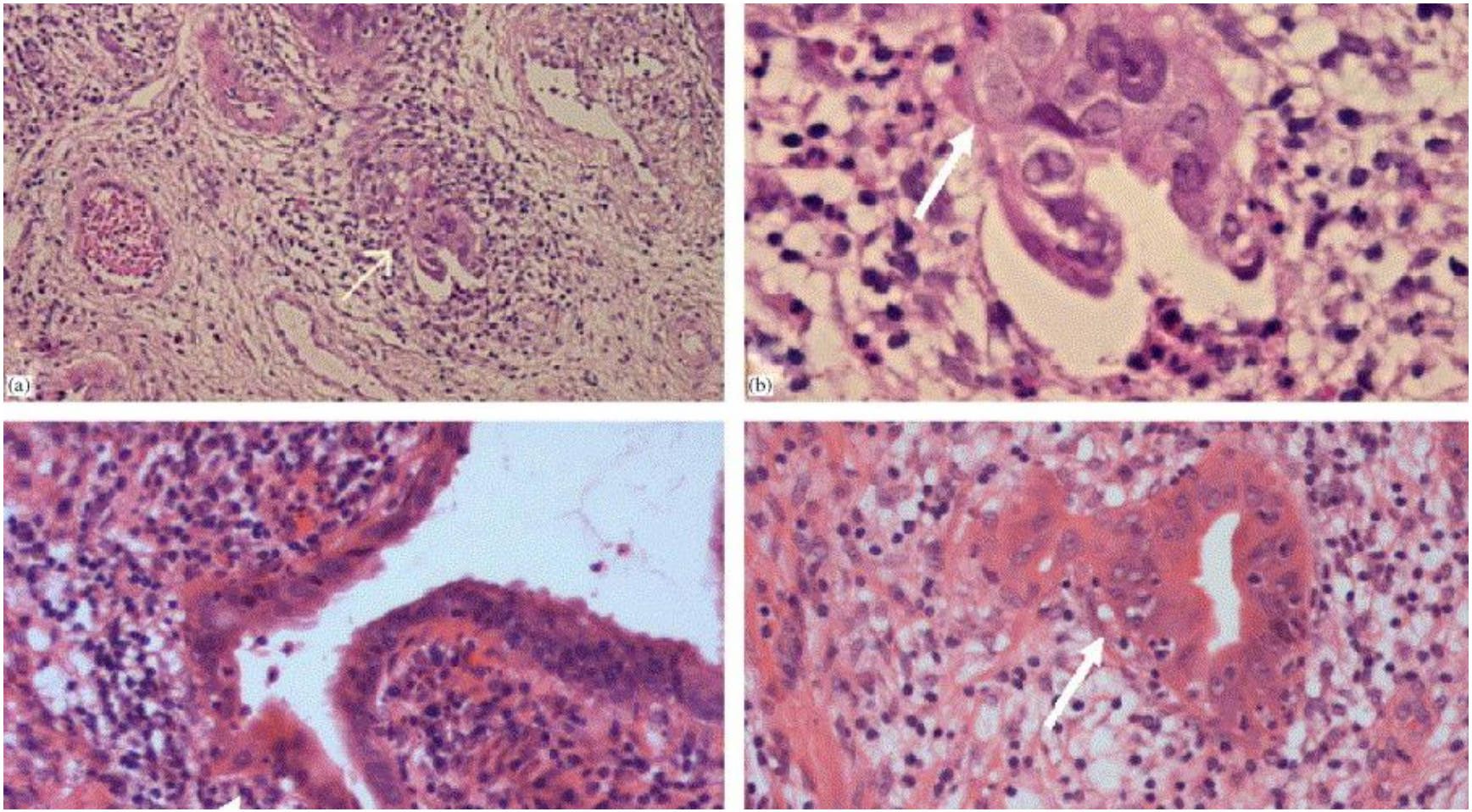

Another feature suggestive of invasion is the thinning and attenuation or stretching of part of the glandular wall in an ‘elastic band-like’ manner (arrows in a and b). The thin stretched glands in (c) and (d) are from frankly invasive carcinoma.

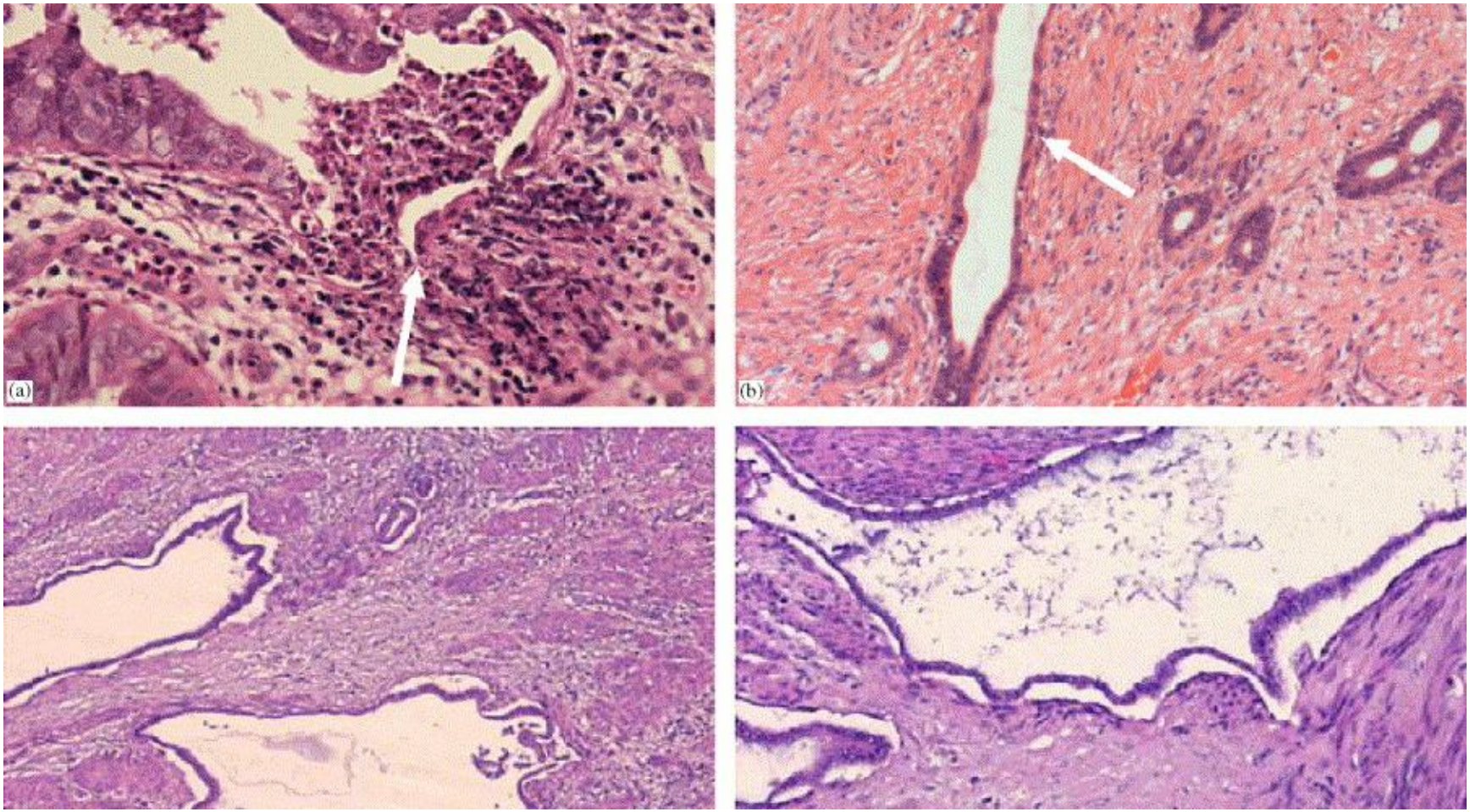

AIS with foci of early stromal invasion involving the entire thickness of the LLETZ. Notice ‘elastic band-like’ pattern (arrows in c and d) and a thickened blood vessel (a rectangle in d).

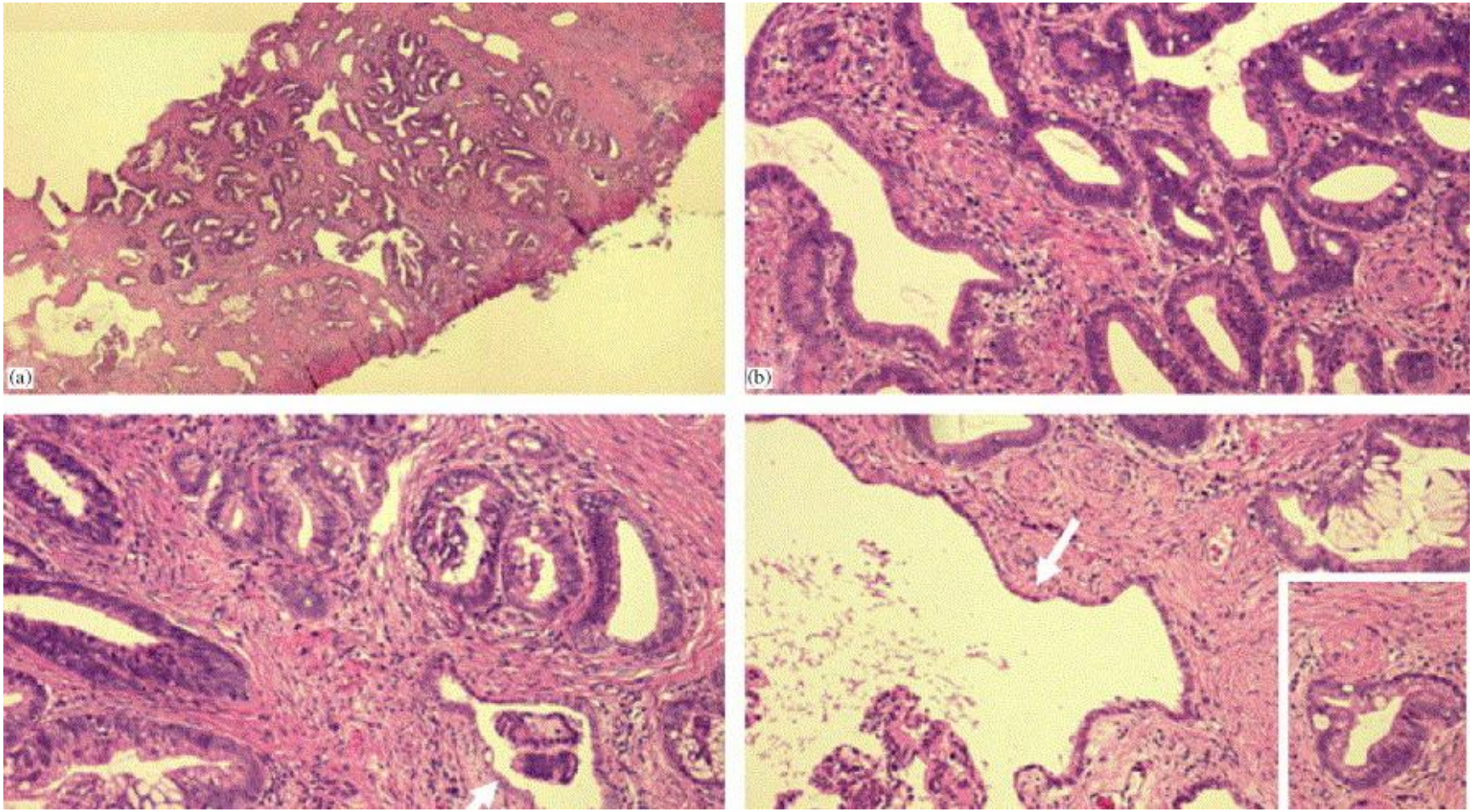

Cervical adenocarcinomas with no clear evidence of invasion

- **Minimal deviation adenocarcinoma (MDA; adenoma malignum)**
- two histological subtypes: endocervical and endometrioid.
- the glands are often irregular in size and shape and lined predominantly by mucin-containing columnar epithelial cells with basal nuclei

- Once the diagnosis is suspected on architectural grounds, it is important to search for mitotic figures and for features indicative of invasion, such as squamoid change, thickened blood vessels, thinning and attenuation and stromal nests or single cells
- The tumours typically exhibit deep invasion of the cervical wall, and a portion of the infiltrating tumour is often associated with a stromal response. Minor foci of tumour with a less well-differentiated appearance are present in over 50% of cases.

- The tumours typically exhibit deep invasion of the cervical wall, and a portion of the infiltrating tumour is often associated with a stromal response.
- Minor foci of tumour with a less well-differentiated appearance are present in over 50% of cases.

Endocervical subtype of MDA (adenoma malignum) diagnosed on LLETZ. There is clear architectural abnormality of the abnormal glands (a and b), mitotic figures (c) and some features of invasion such as ‘elastic-band’ pattern and inflammatory response (arrow in d).

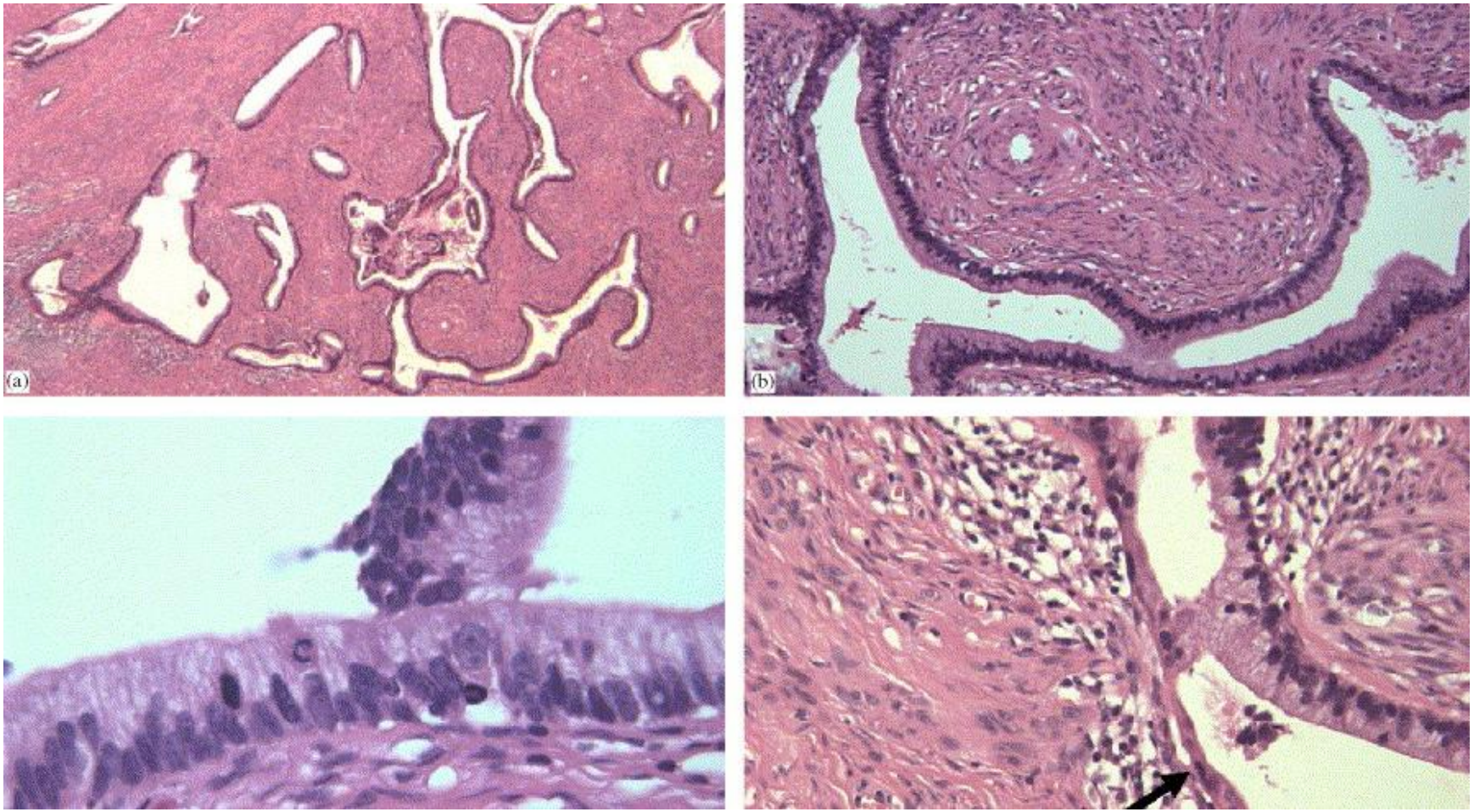

Endocervical subtype of MDA (adenoma malignum) discovered incidentally at hysterectomy for ovarian mucinous tumour. There is clear architectural abnormality of the abnormal glands (a). Features of invasion are seen: thickened blood vessels (arrow in a), isolated nests and single cells within the stroma (arrows a–c) and squamoid change (circle in d).

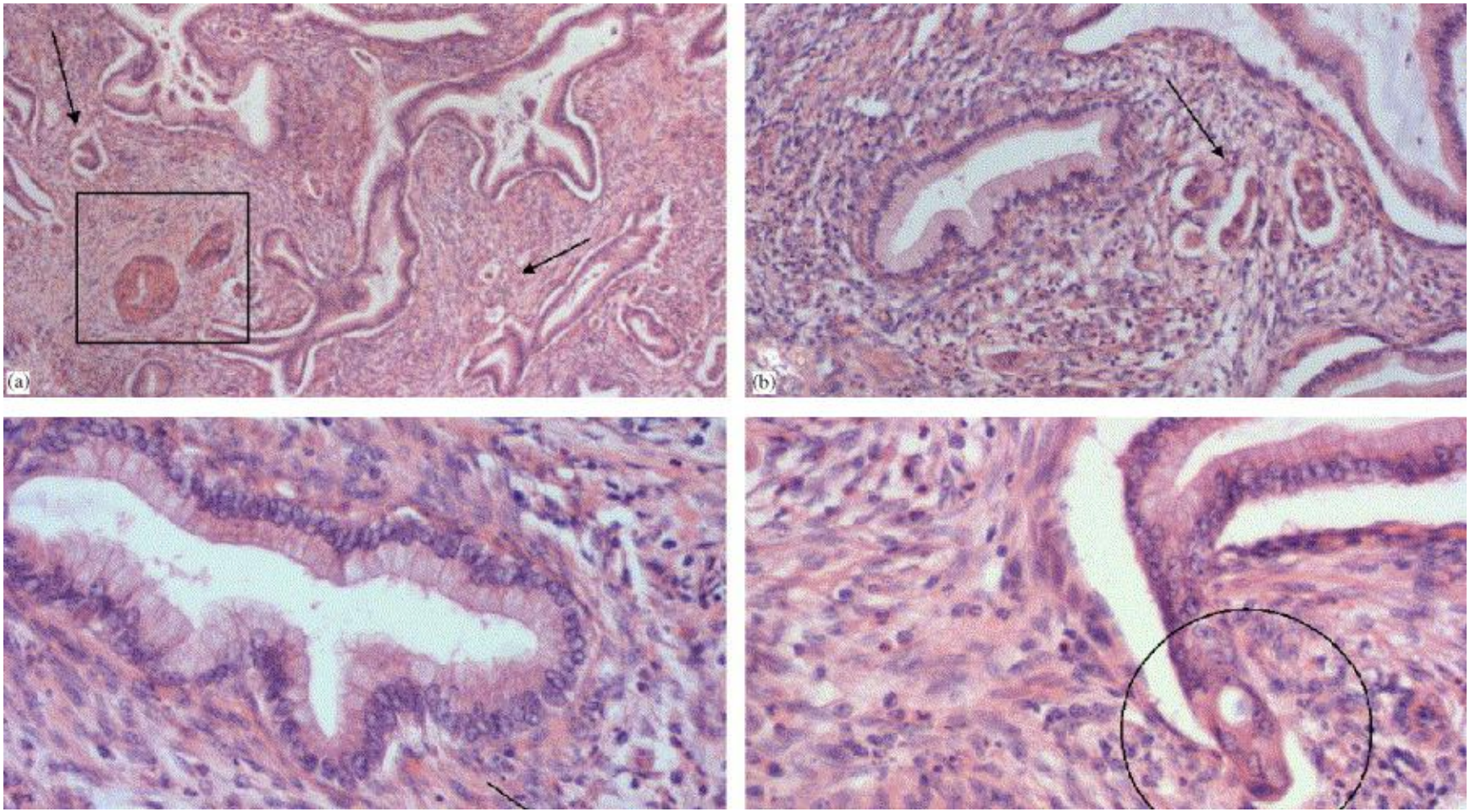

Adenoid basal carcinoma/epithelioma

- Nests or cords of small basaloid cells with prominent peripheral palisading of cells and no significant stromal reaction
- An associated neoplastic squamous lesion is present in 92% of patients, including high-grade CIN and microinvasive squamous cell carcinoma.
- Foci of squamous differentiation in some portions of the small nests are sometimes seen.
- Occasionally, the tumour cells are arranged in slender cords that penetrate deep into the stroma and are surrounded by myxoid matrix resembling morphea-type basal cell carcinoma of the skin.

- The tumour cells are usually small and uniform, with scanty cytoplasm and dark, oval nuclei without conspicuous nucleoli.
- The acini are lined by a single layer of cuboidal or columnar basaloid, vacuolated or mucin producing epithelial cells.
- The squamous cells seen within some of the nests are often uniform and cytologically bland and only occasionally atypical. Mitotic figures are usually sparse.

- the basaloid cells of adenoid basal carcinoma are positive for cytokeratins 14, 17 and 19 and therefore resemble reserve cells of the cervical epithelium.
- The acini are highlighted by their expression of EMA and CEA and p53 gene alterations are common
- The tumour is usually asymptomatic, occurs in postmenopausal women and may be associated with adenoid basal hyperplasia of the cervix
- non-aggressive behaviour

Adenoid basal carcinoma of the uterine cervix showing nests of small basaloid cells with peripheral palisading of cells and no significant stromal reaction. These are present deep into the cervical stroma. Notice mitotic figures (circles in d).

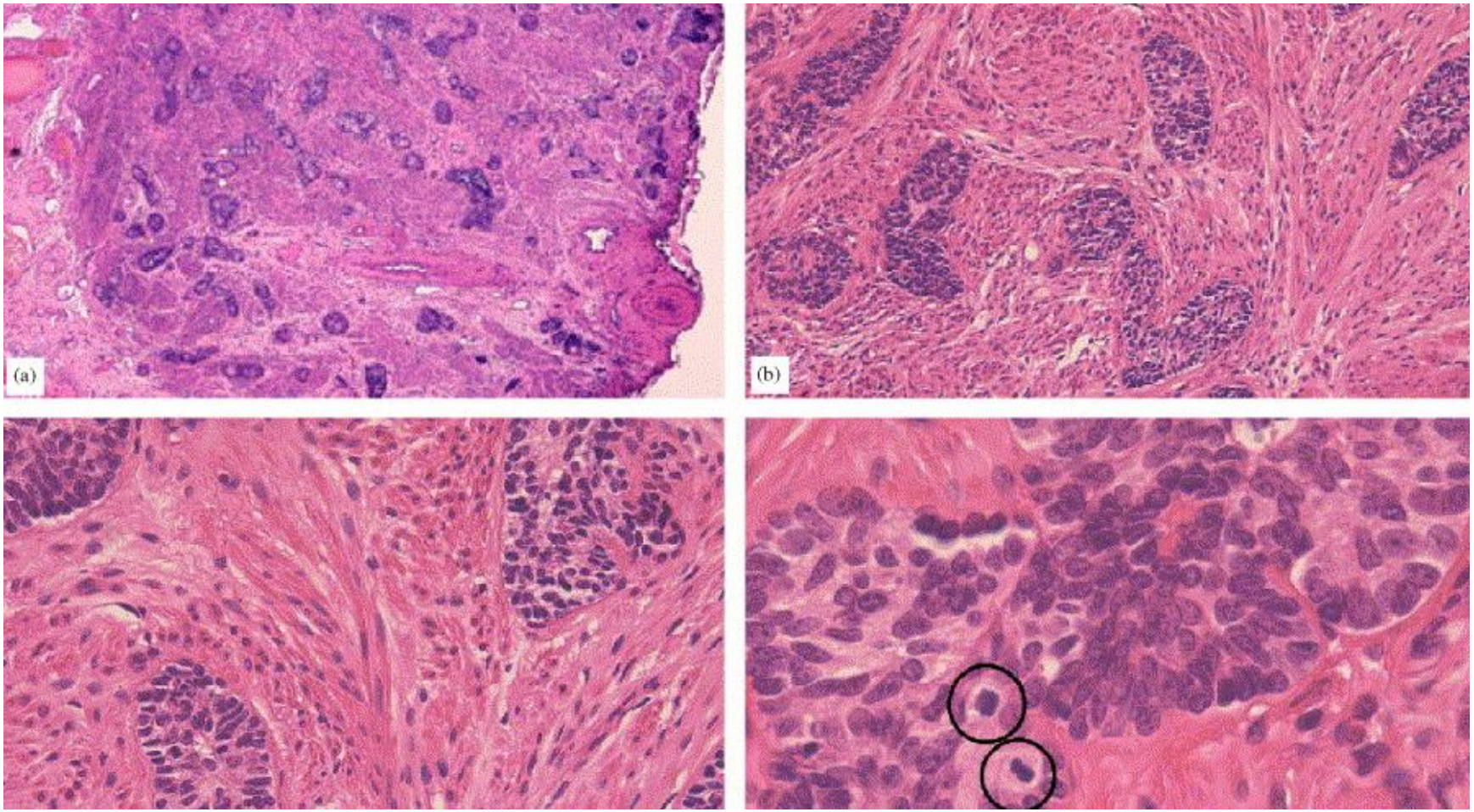

Postmenopausal basaloid reserve cell change' consisting of small basaloid buds and nests linked to the basal layers of the endocervical epithelium.

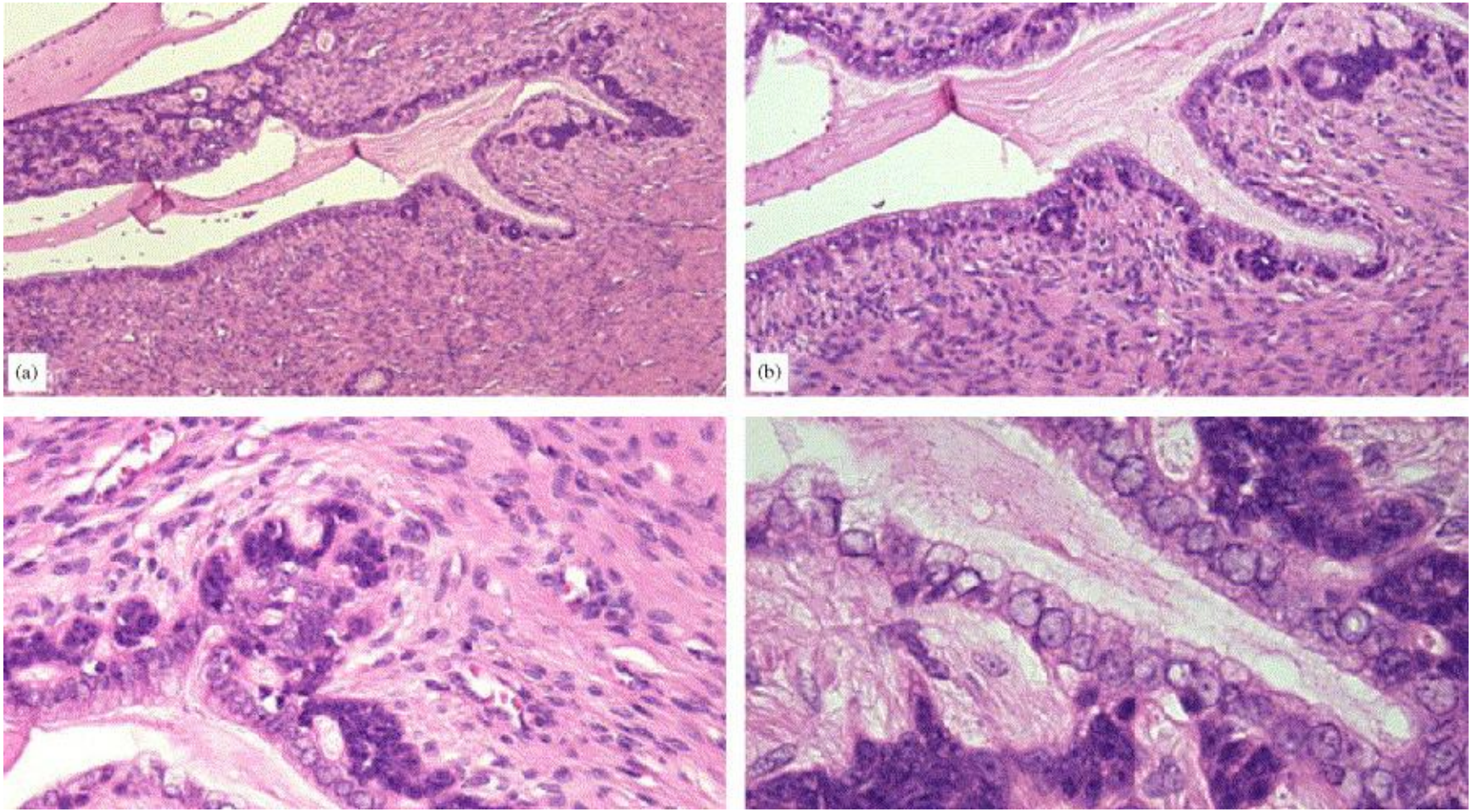

Postmenopausal basaloid reserve cell change’ consisting of plexiform cords within unreactive normal stroma.

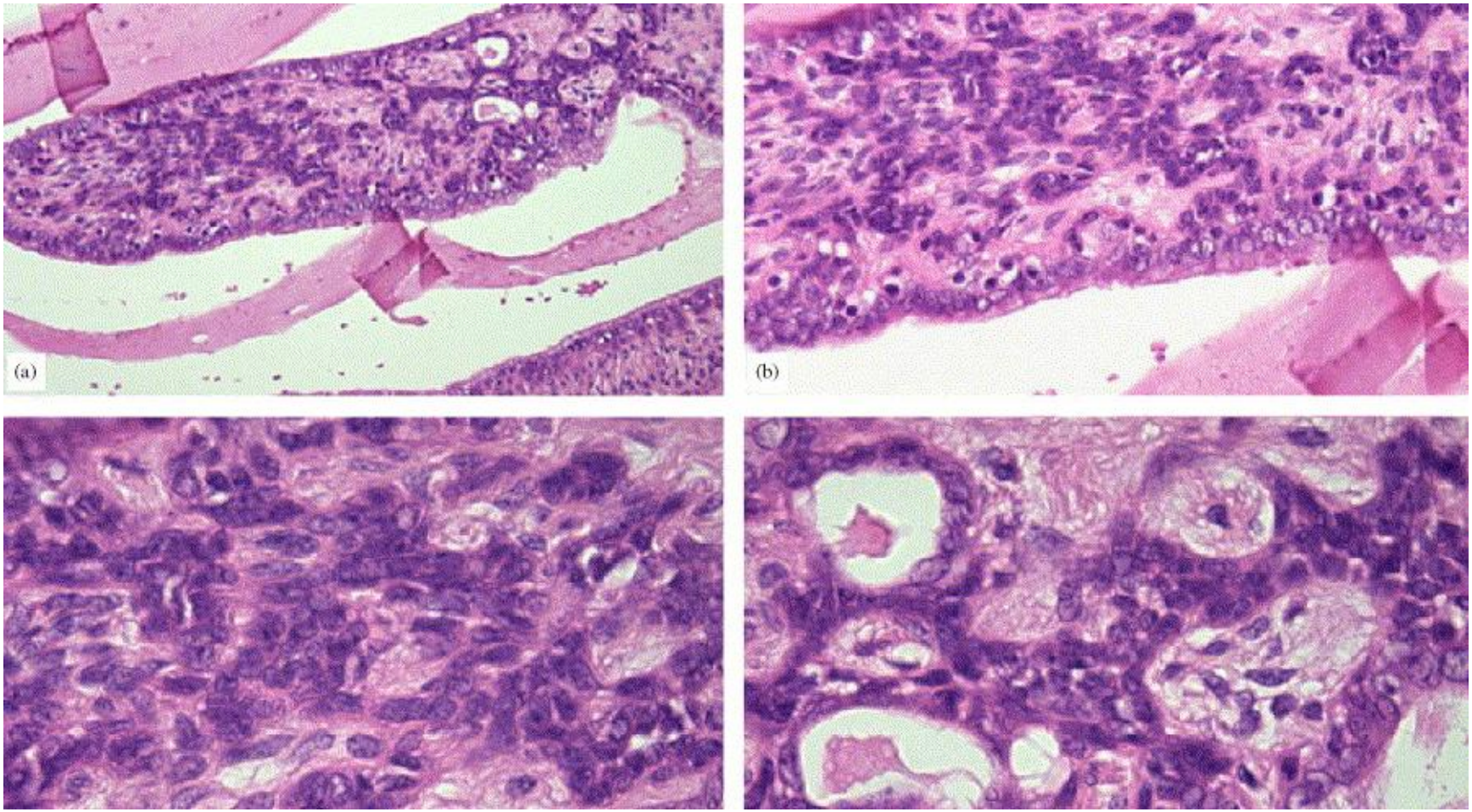

Microcystic adenocarcinoma

- characterized by a predominant cystic component simulating benign cervical lesions, but admixed with recognizably malignant glands
- This lesion often masquerades as various benign cervical lesions including type B tunnel clusters, deep Nabothian cysts, mesonephric hyperplasia, lobular endocervical gland hyperplasia, and endocervical gland hyperplasia (not otherwise specified).

Microcystic adenocarcinoma is characterized by a predominant cystic component simulating benign cervical lesions, but admixed with recognizably malignant glands.

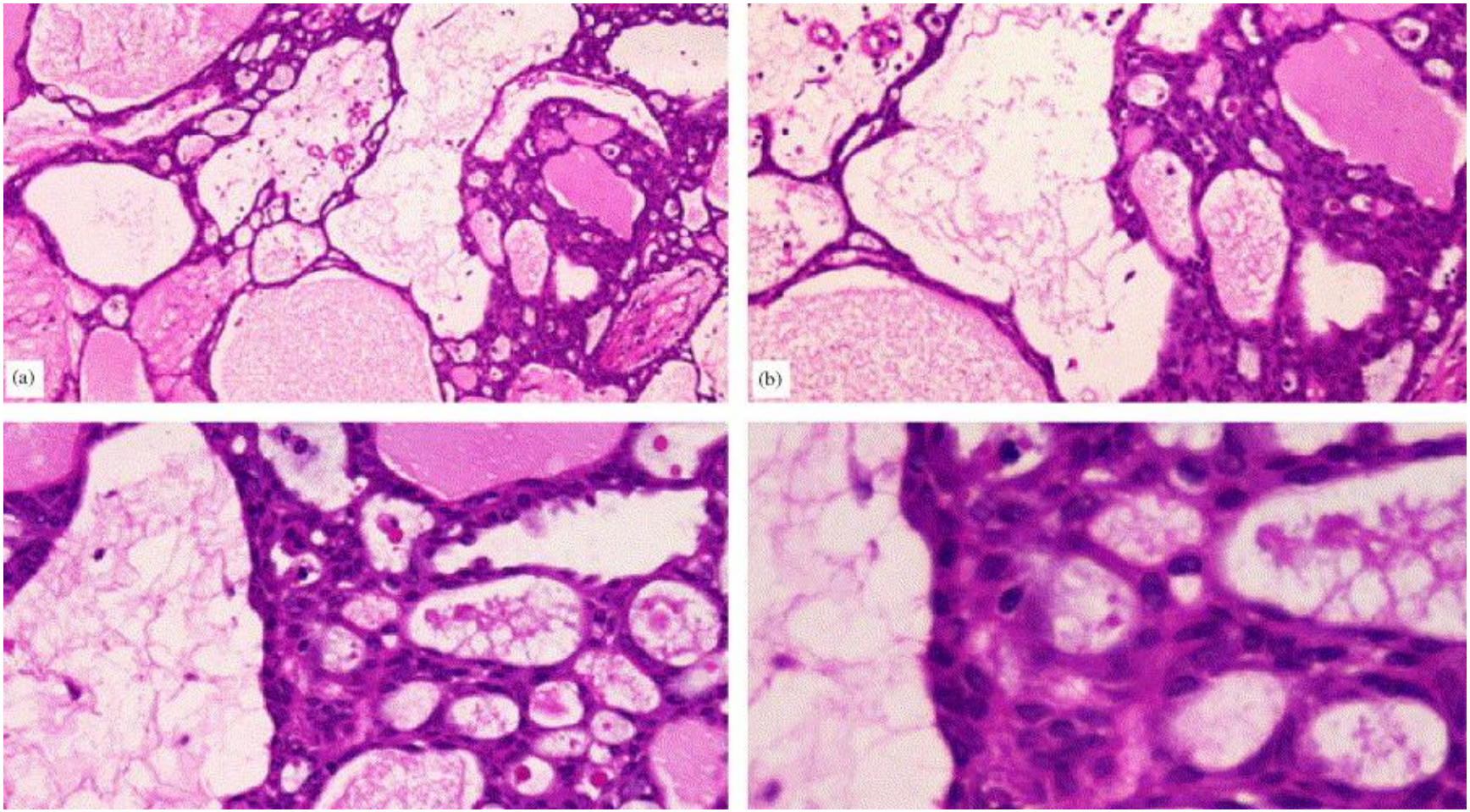

Mimics of invasive adenocarcinoma

- **tunnel clusters**
- Type A displays tightly packed small glands lined by columnar mucinous epithelium, whereas type B consists of closely packed dilated glands containing inspissated mucin, lined by cuboidal to flattened mucinous epithelium.
- Both types have a lobular architecture.

- **Lobular endocervical glandular hyperplasia** (LEGH)
- a lobular proliferation of variably sized rounded endocervical glands, sometimes clustered around a central dilated gland
- The tall mucinous columnar lining shows bland cytology, although reactive changes and occasional mitoses may be seen.
- The surrounding stroma may demonstrate increased cellularity and a periglandular chronic inflammatory infiltrate.

Type B tunnel clusters exhibit crowded glands that have a lobular arrangement and bland lining epithelium (A).

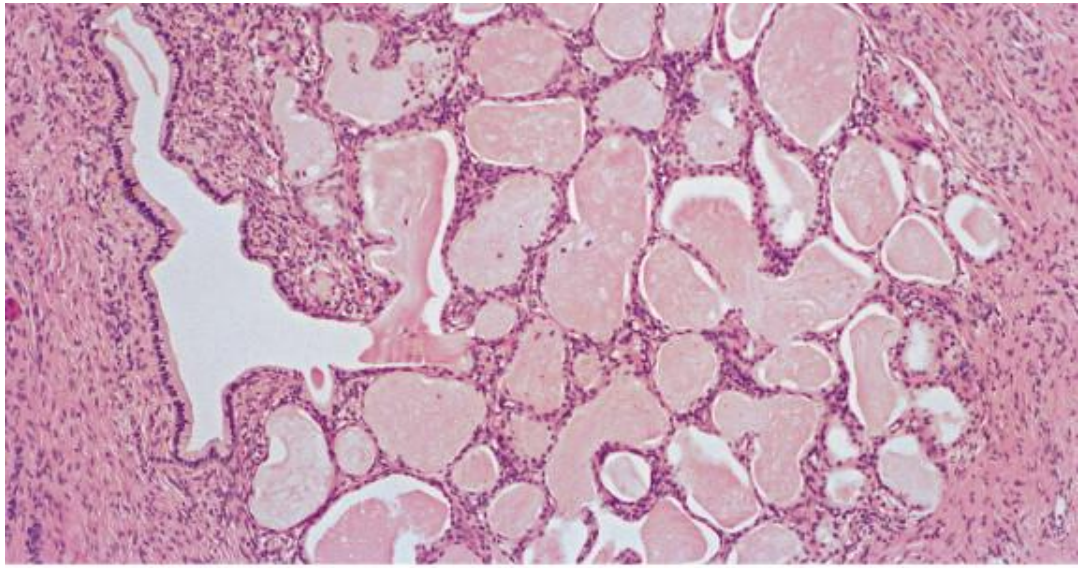

Lobular endocervical gland hyperplasia is well demarcated and it is composed of a larger central duct surrounded by smaller acini. (B)

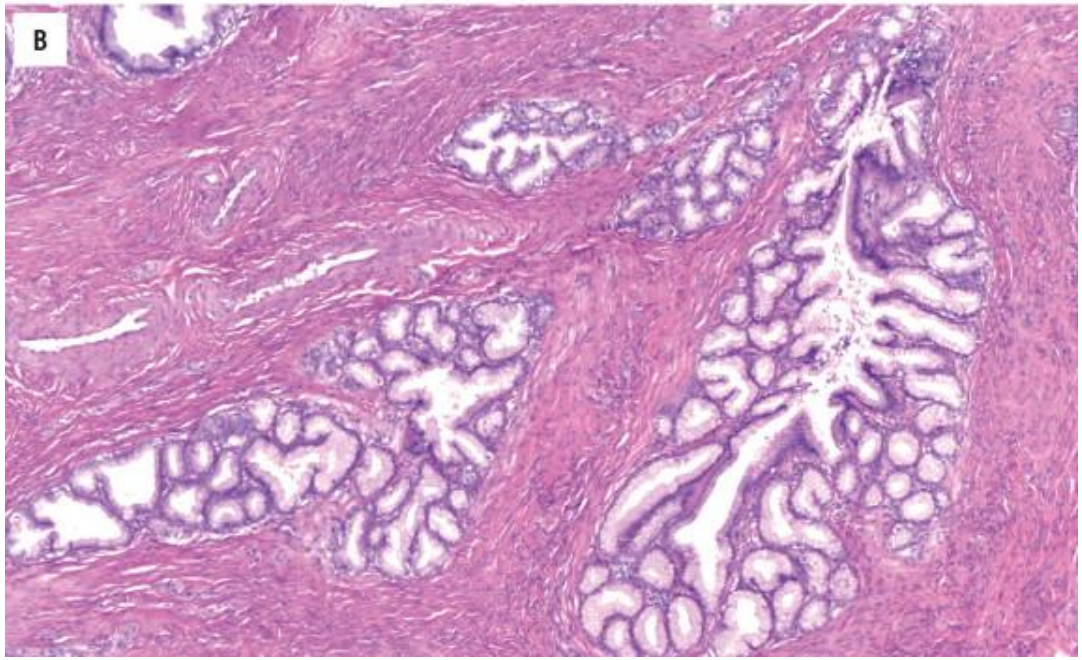

Diffuse laminar endocervical hyperplasia (DLEH)

- a diffuse proliferation of well-differentiated, evenly spaced endocervical glands which are well-demarcated from the underlying stroma and form a discrete layer
- confined to the inner third of the cervical wall.
- A prominent inflammatory infiltrate may cause reactive cytologic atypia.
- Periglandular stromal oedema may mimic a desmoplastic stromal reaction and raise concern about an MDA.
- Features in favour of DLEH include its superficial location and lack of irregular stromal infiltration.

Microglandular hyperplasia. Note cribriform architecture, inflammatory infiltrate/exudate, associated squamous metaplasia and bland cytologic features.

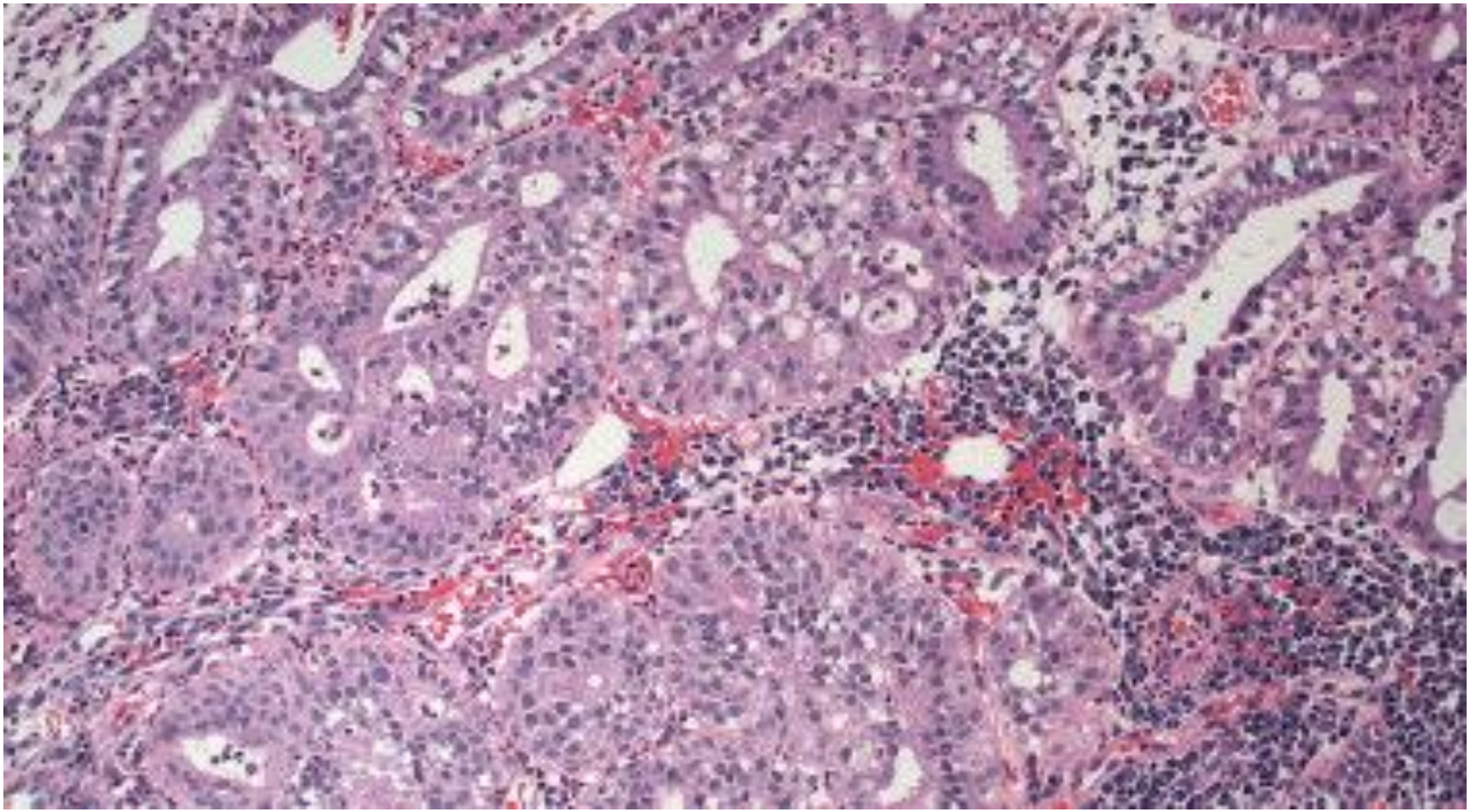

Endocervical adenomyoma. Benign endocervical glands have irregular shapes and the smooth muscle is hyalinized simulating desmoplastic stroma (C); however, in some areas fascicles of banal smooth muscle cells are readily identified (D).

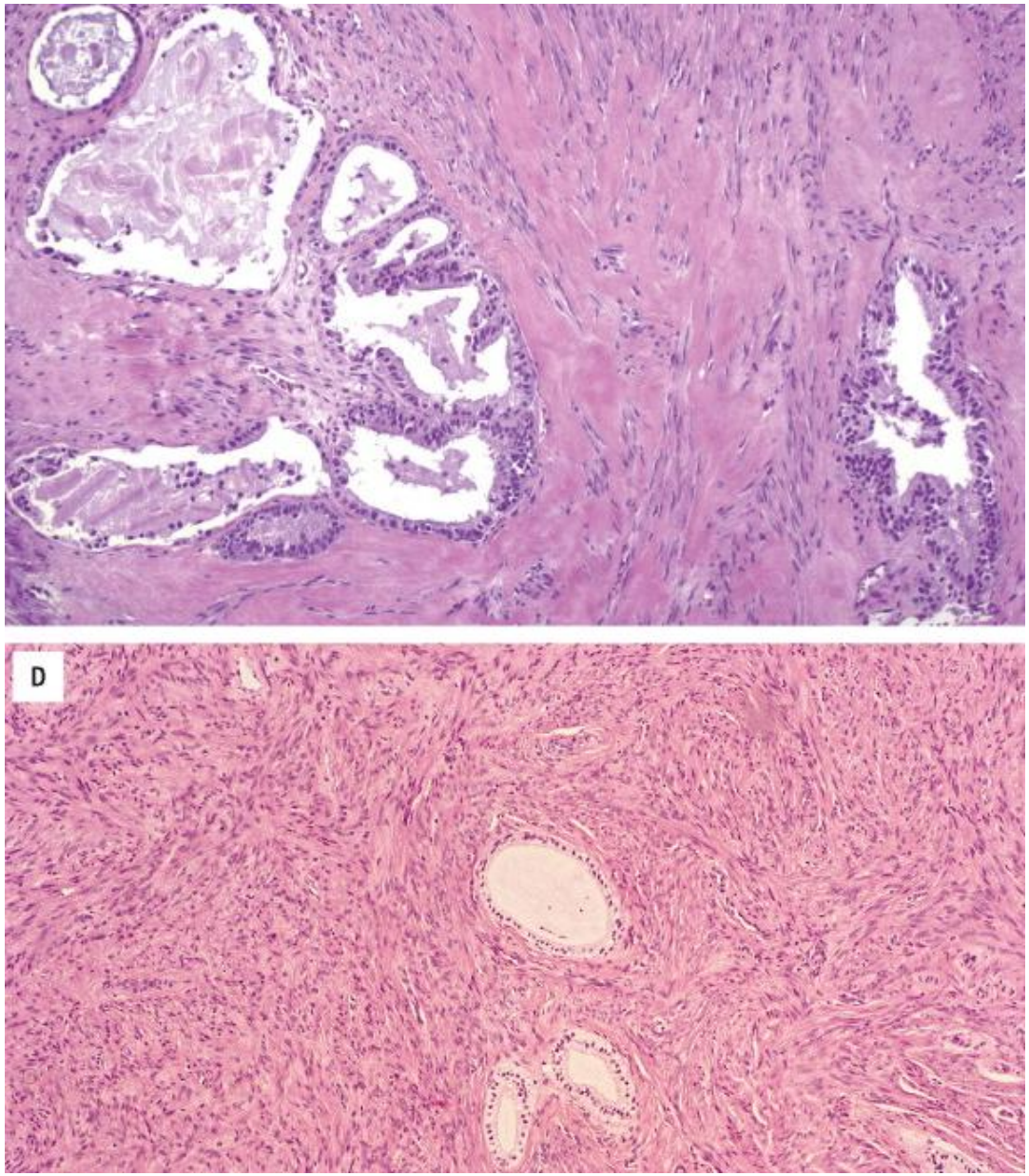

Mesonephric hyperplasia, lobular type. Mesonephric duct remnant (upper part of image) and lobe-shaped glandular proliferations budding off.

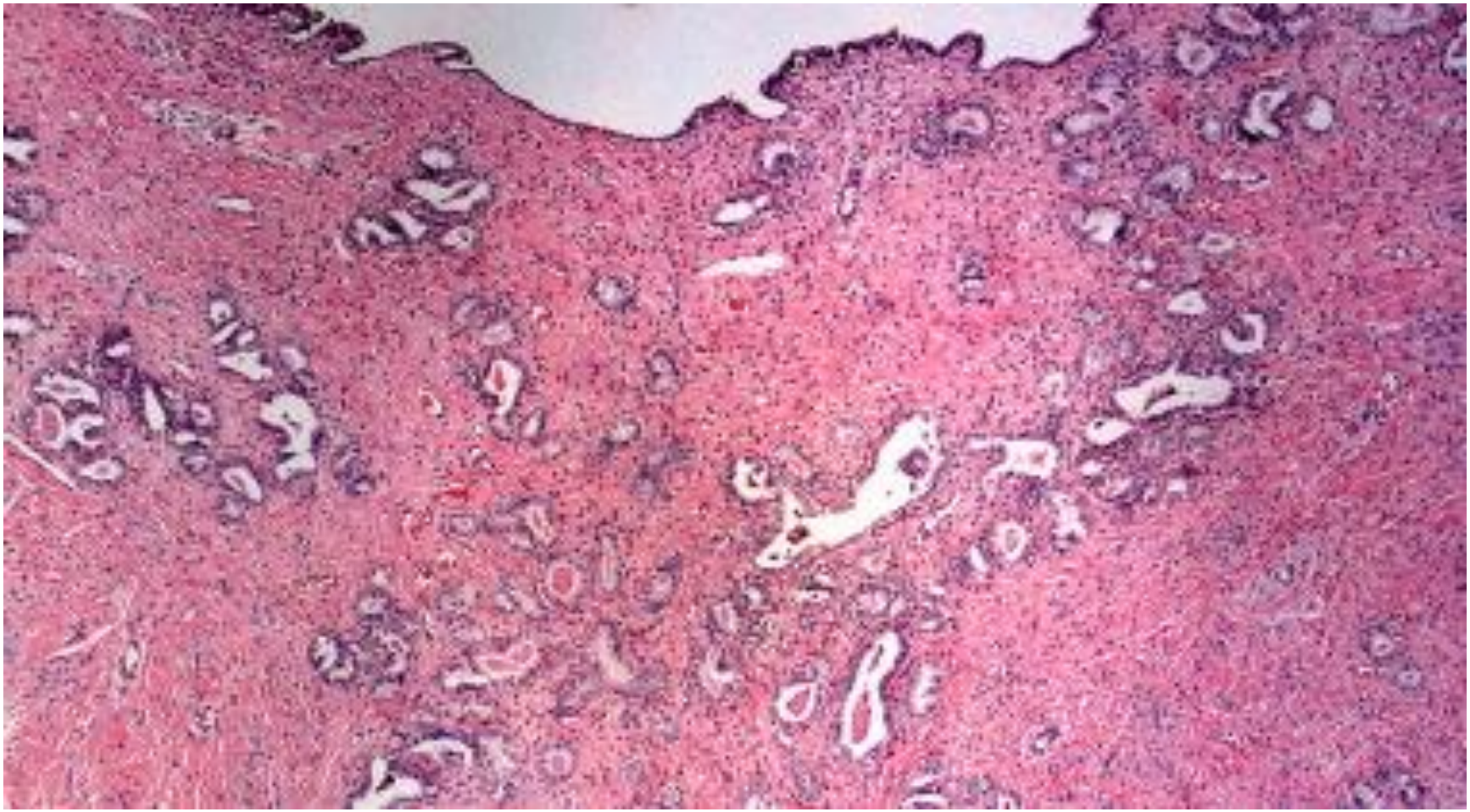

Arias-Stella change. Marked nuclear atypia including hobnailing

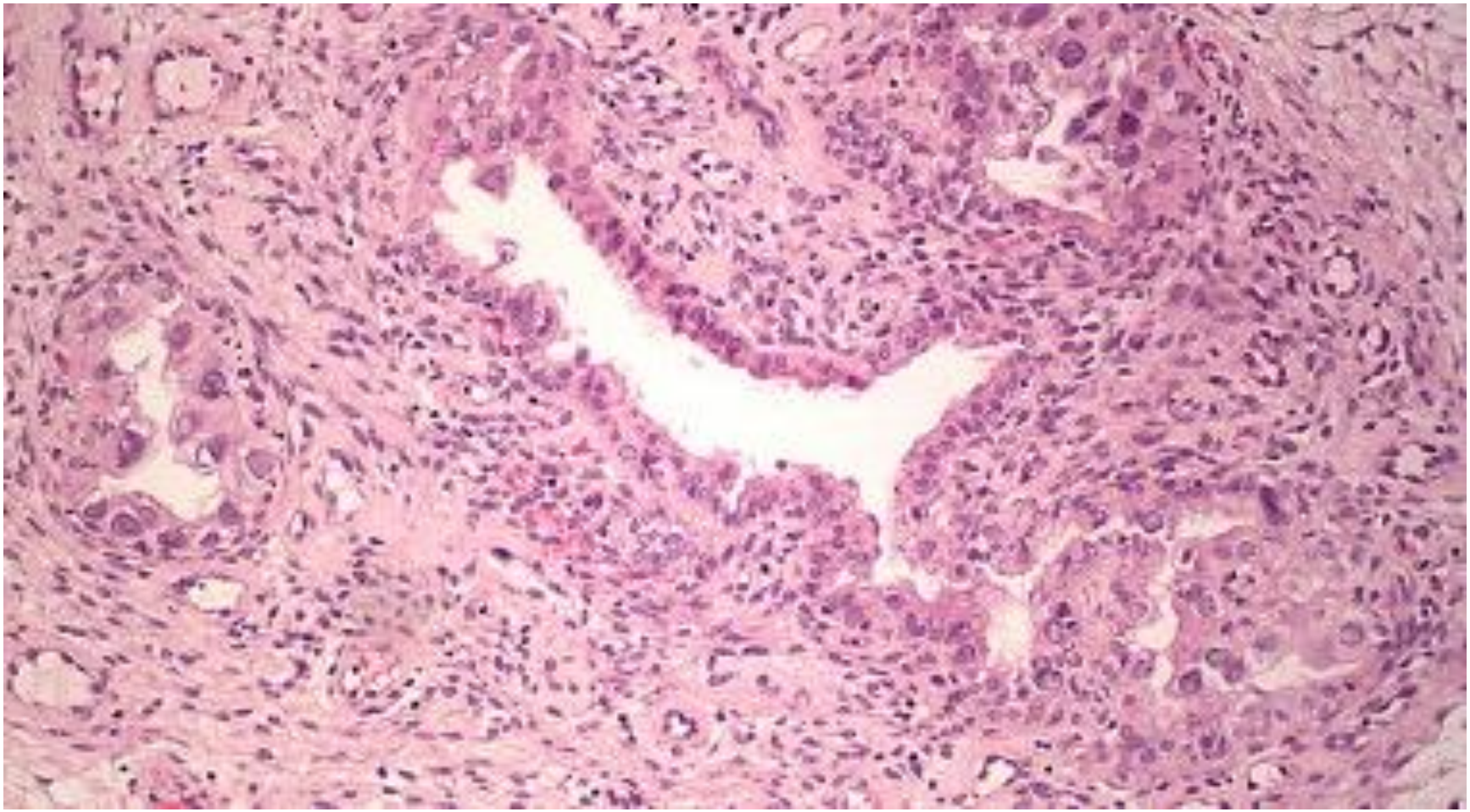

Endocervical vs endometrial

Endoemtrioid adenocarcinoma

H and E clues:

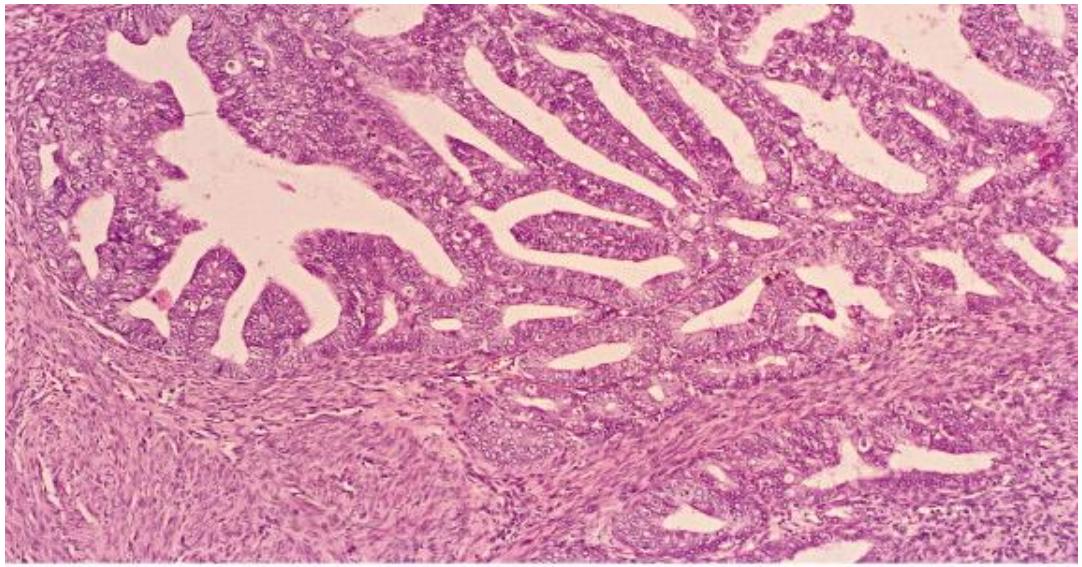

Vs Mucin poor cervical adenocarcinoma: Negative staining for CEA, positive staining for ER, PR, and vimentin. p16, however, may be focally positive in endometrial adenocarcinomas.

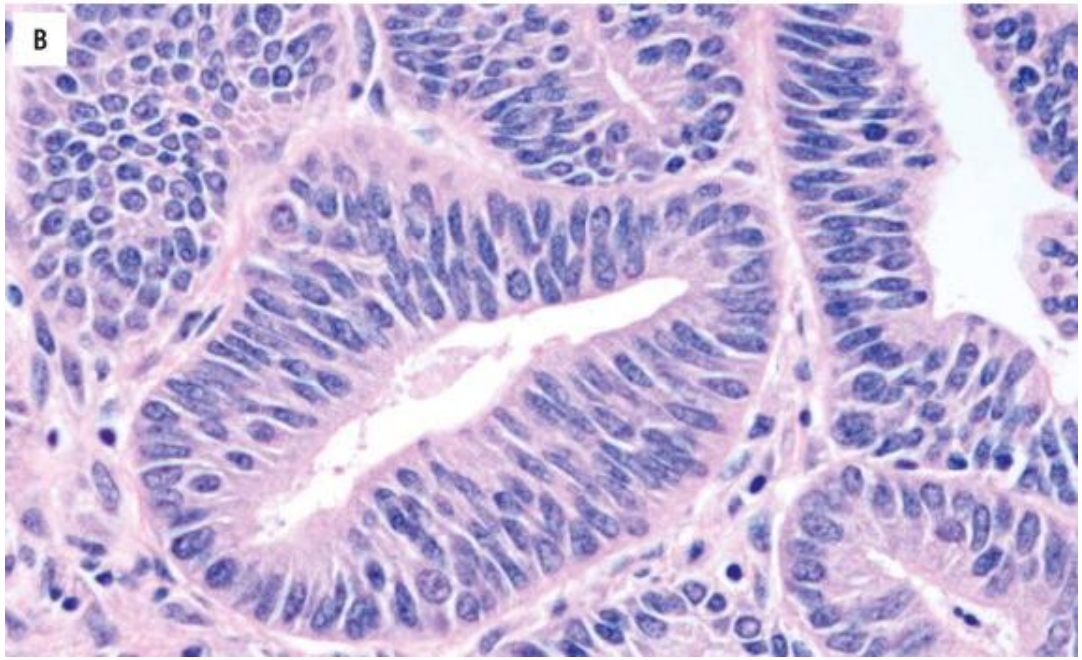

It’s OK to be uncertain

- Even the best pathologists don’t know for sure 10% of the time with early invasive adenocarcinoma of the cervix

Danger Danger

- AIS in areas of microglandular hyperplasia or tunnel clusters

A short note on measuring

- Do it from the base of the AIS
- Multiple small foci close together – measure the whole thing
- Multiple small foci far apart – measure each one
- A final size cannot be given when there is AIS or invasive adenoca at the biopsy edge

Endocervical vs endometrial

CEA Vimentin

ER p16

Note: CEA is positive in squamous morules, and can be focally positive in endometrioid ca.

Endometrioid ca cervix less ER positive, still vimentin positive.

P16 patchy in endometrioid – solid in endocervix.

Minimal deviation Adenocarcinoma

- AKA adenoma malignum
- An endometrioid version exists
- Morphologic clues
  - Deep invasion
  - Stromal reaction
  - Focal atypia
  - Angulated glands

- Immuno clues:
- MDA has a gastric phenotype:
  - ABPAS: red (normal = purple/blue)
  - HIK1083
- Variable CEA positivity
- ER and PR negative
- HPV and p16 negative

QUIZ

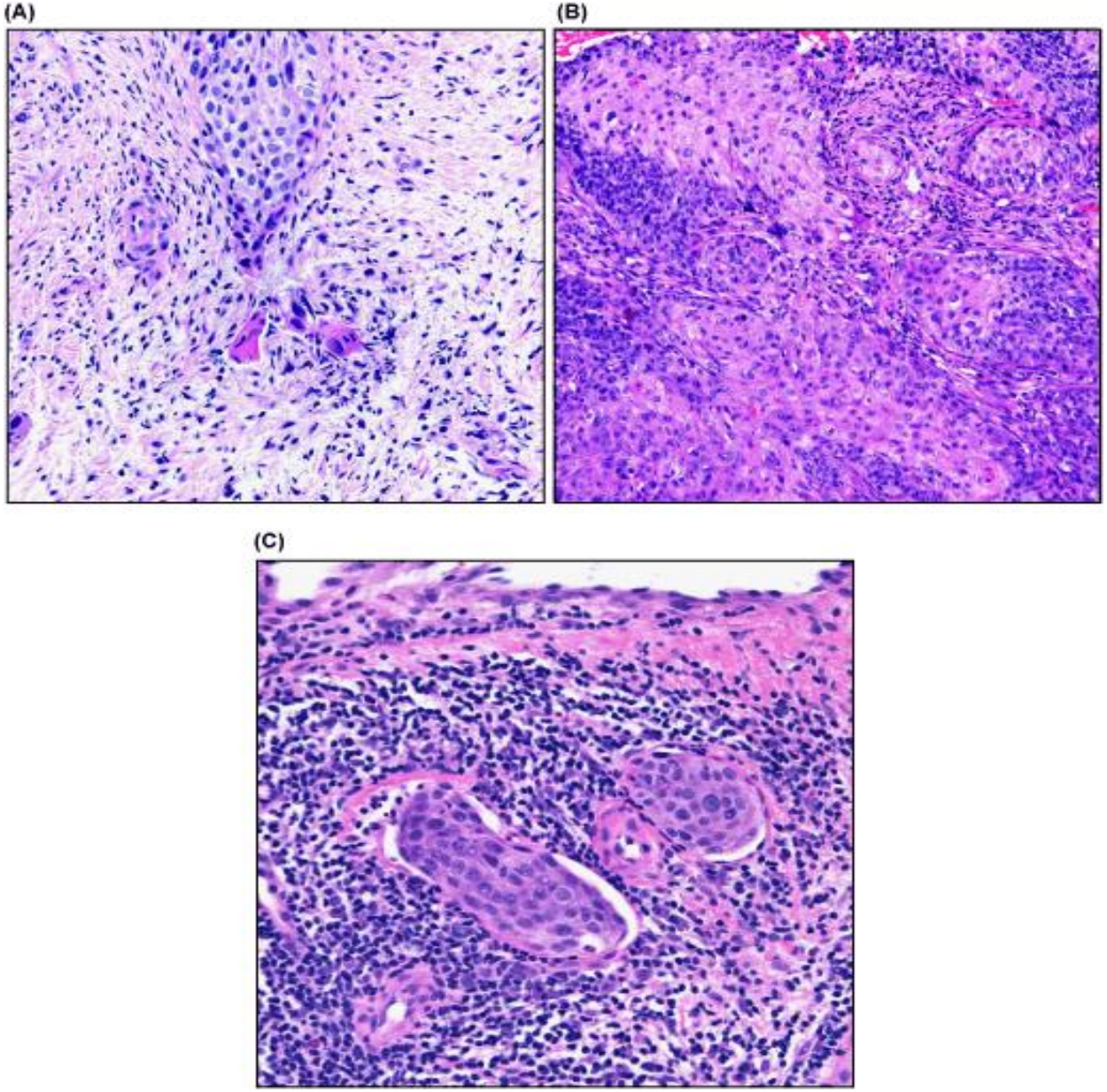
(A)
(B)
(C)

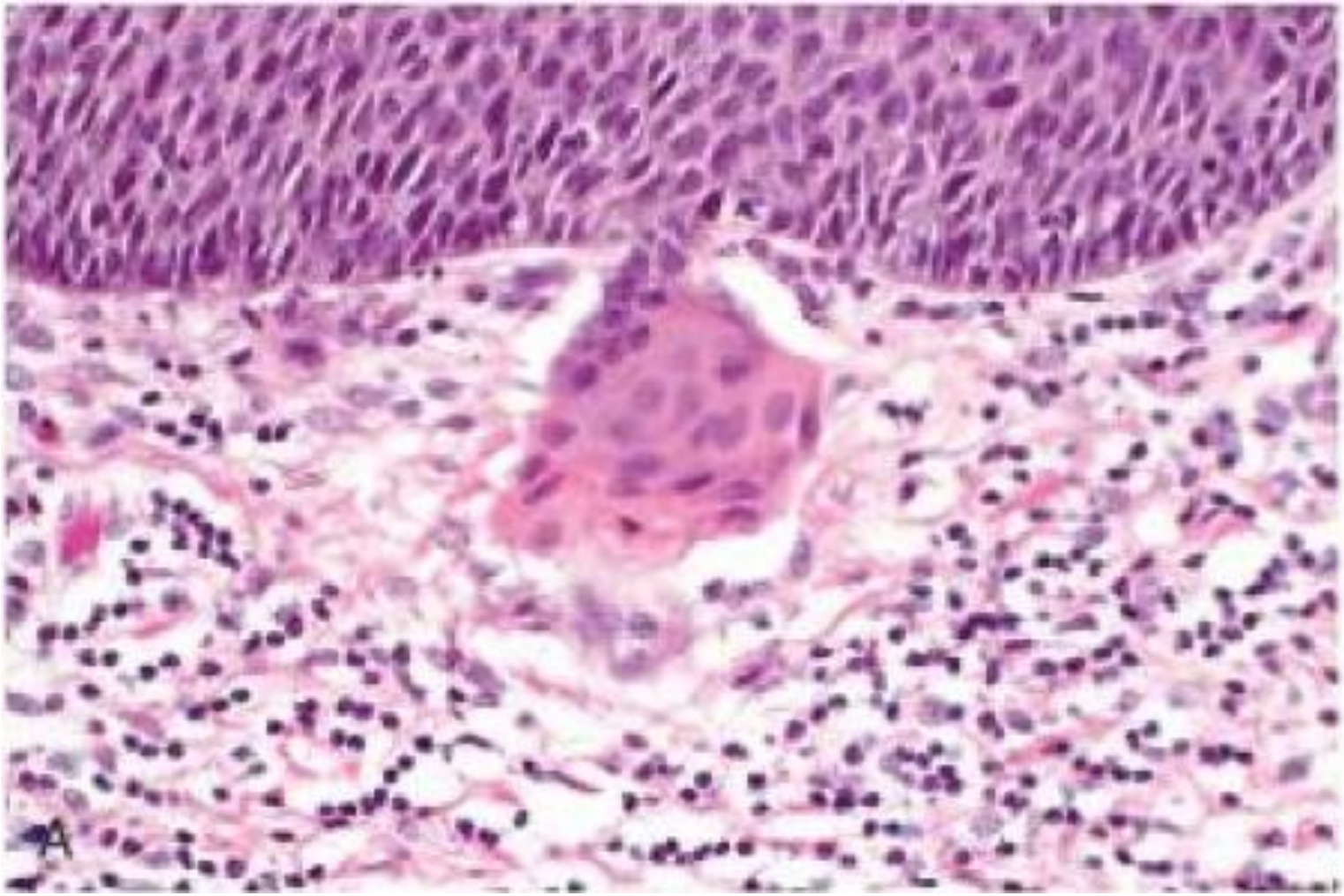
A

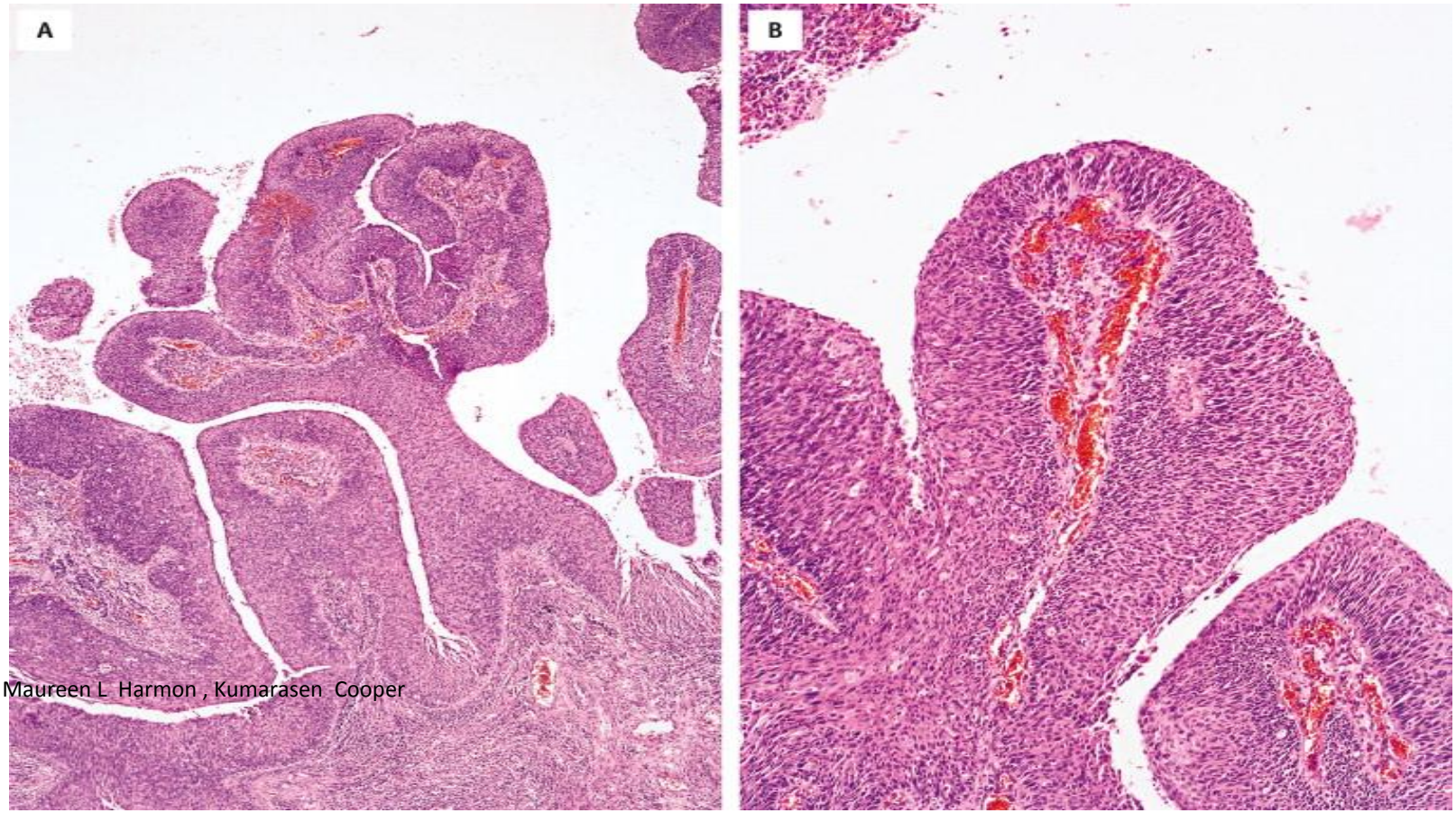

Maureen L Harmon , Kumarasen Cooper

Gynecologic Pathology A Volume in the Series: Foundations in Diagnostic Pathology null 2009 141 - 196

http://dx.doi.org/10.1016/B978-044306920-8.50009-2

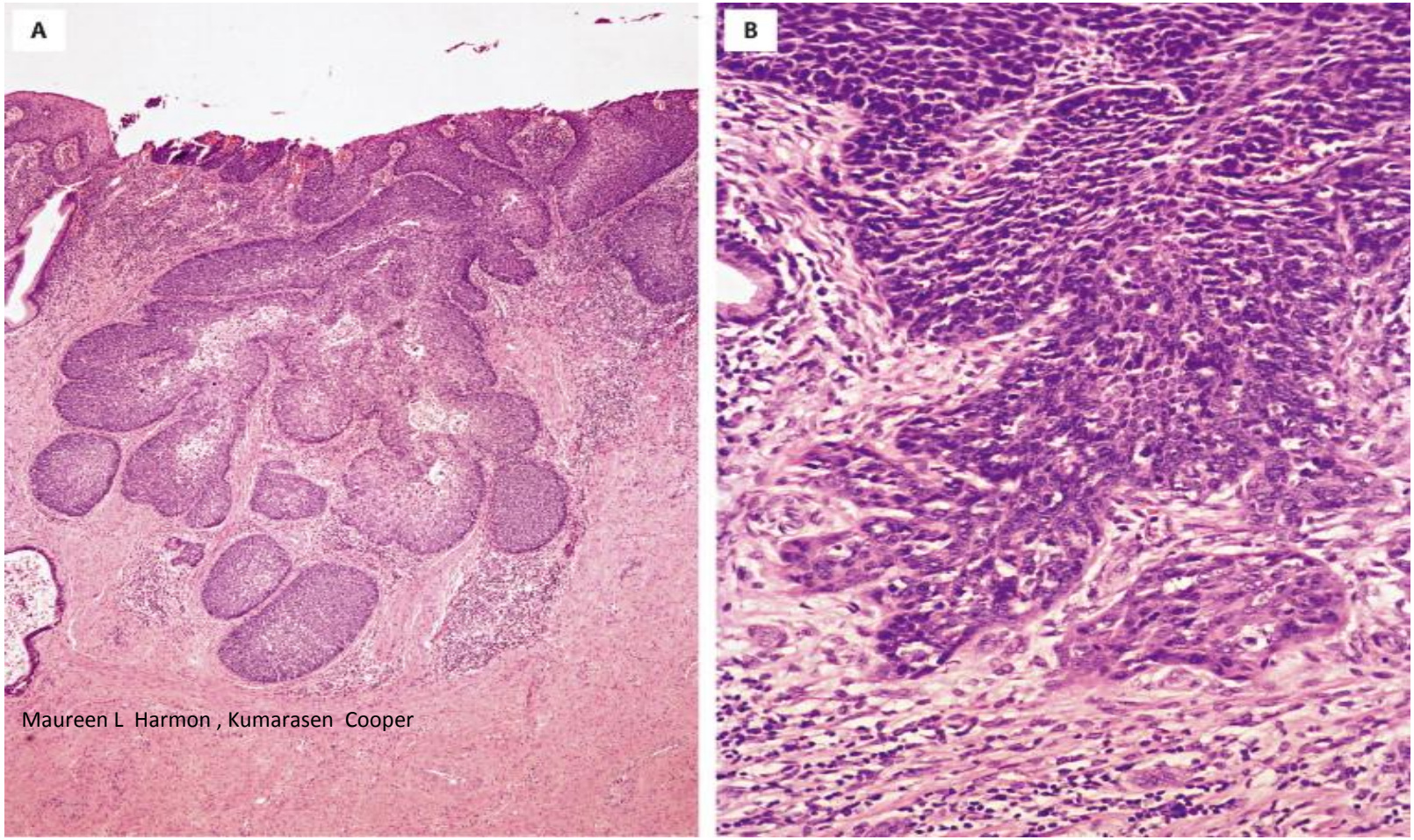

Gynecologic Pathology A Volume in the Series: Foundations in Diagnostic Pathology null 2009 141 - 196

http://dx.doi.org/10.1016/B978-044306920-8.50009-2

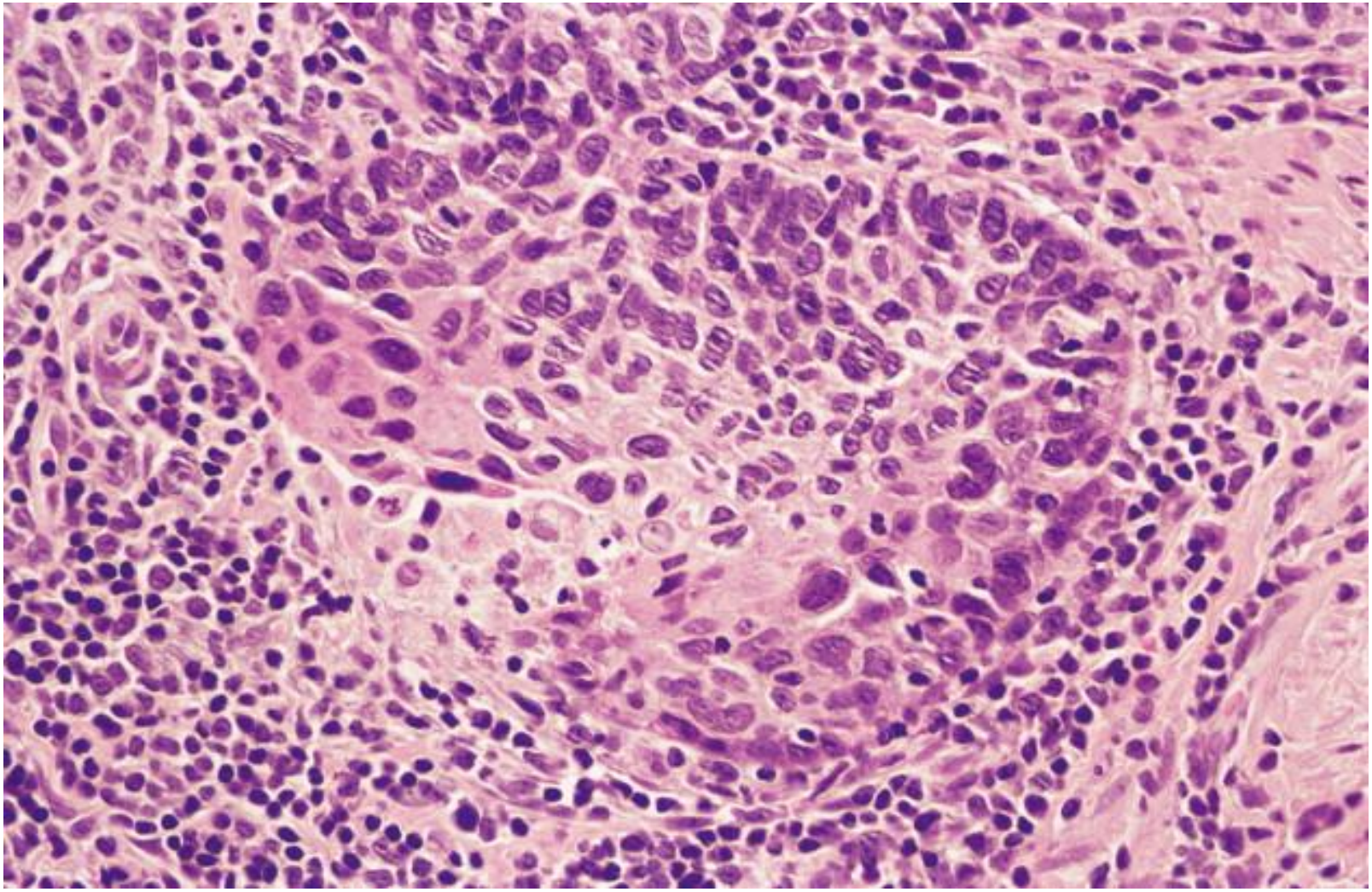

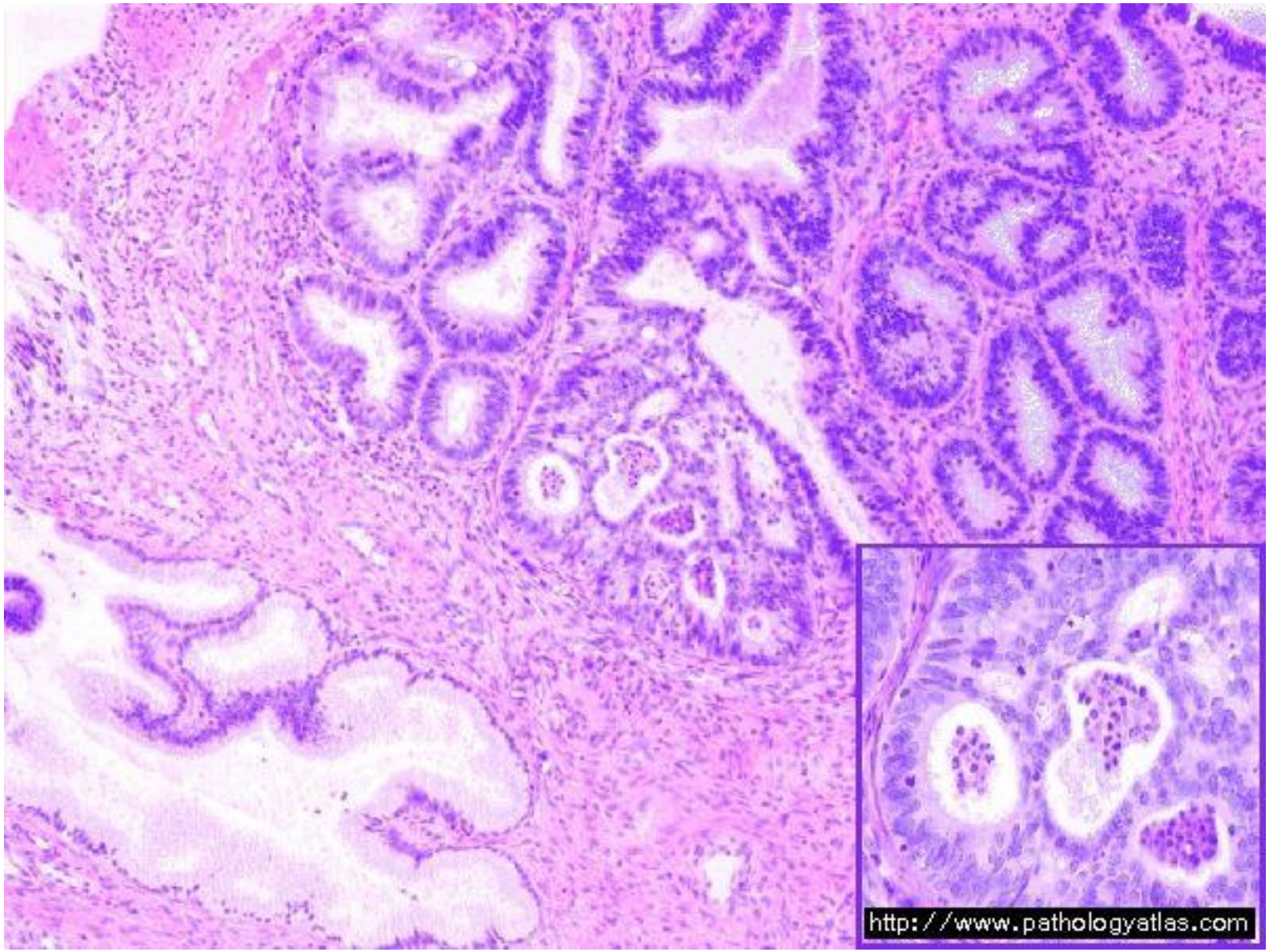
http://www.pathologyatlas.com

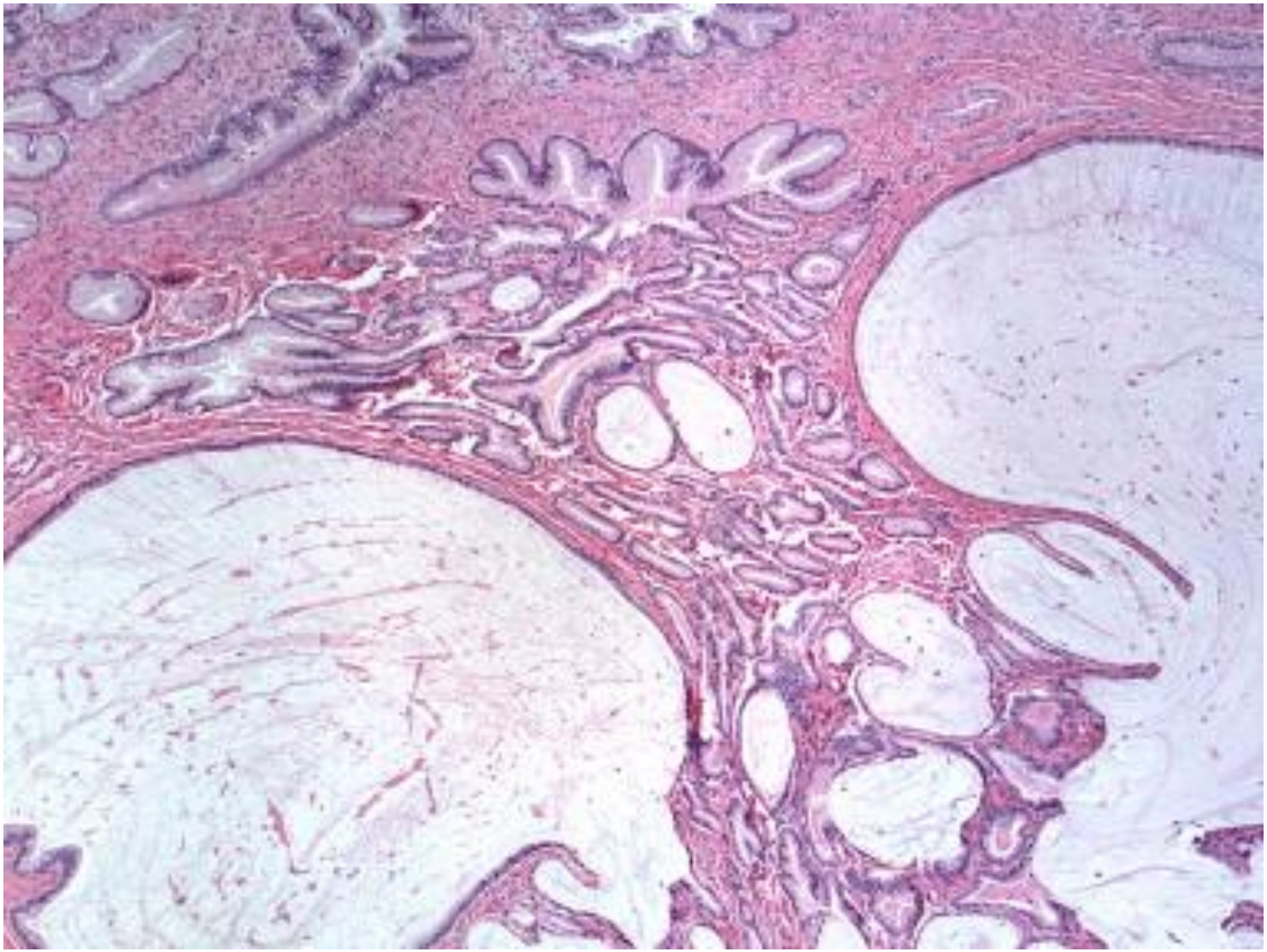

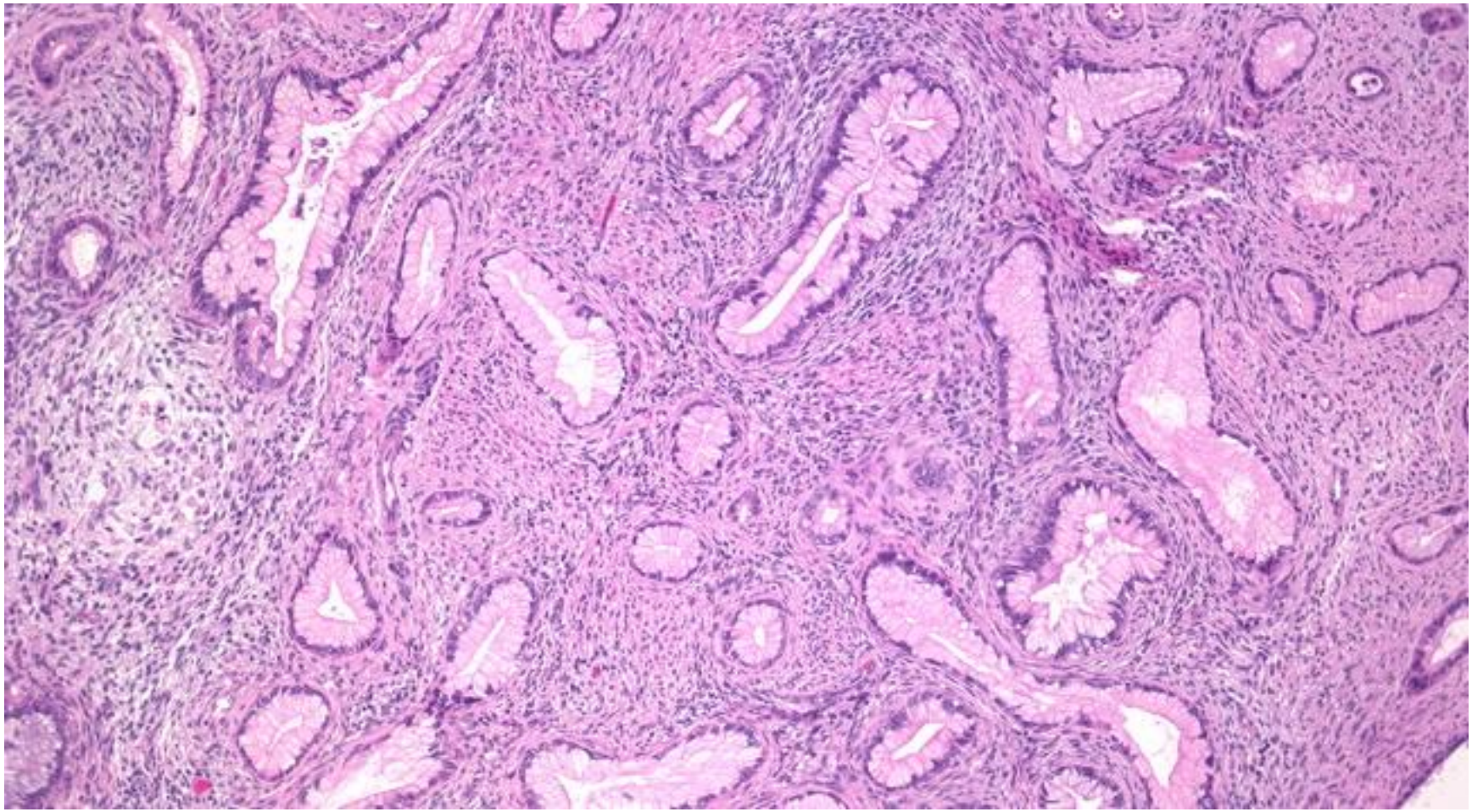

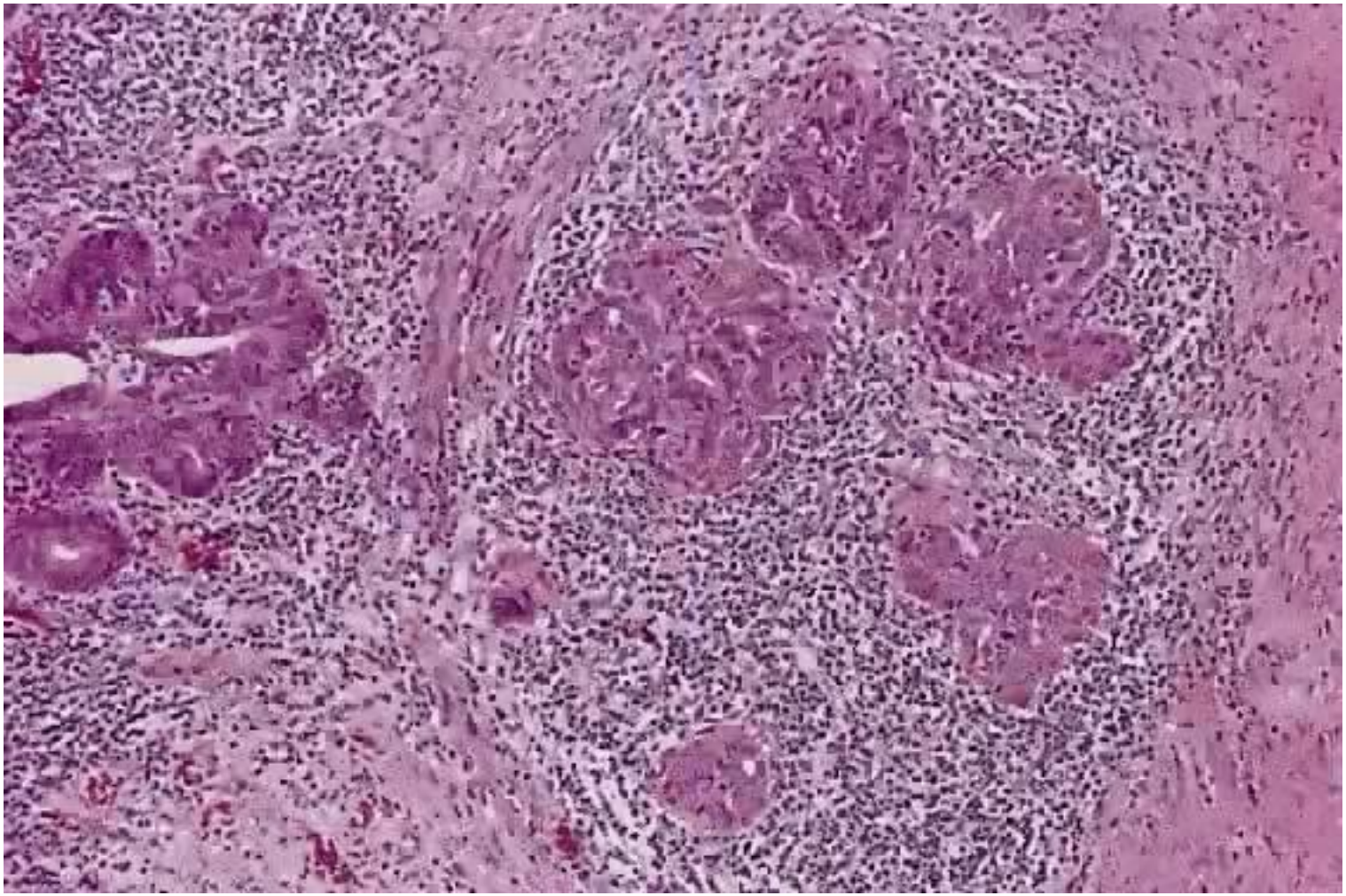

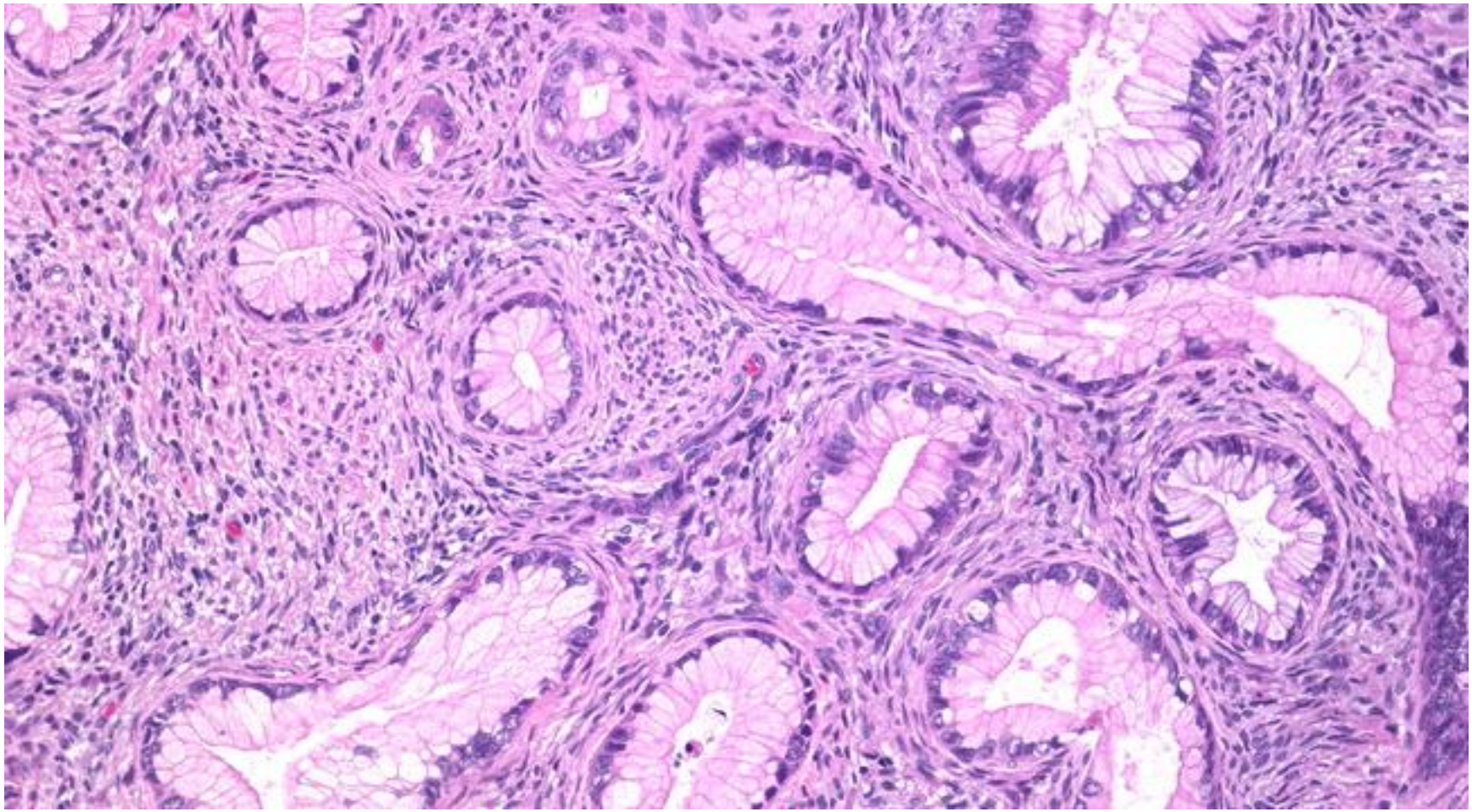

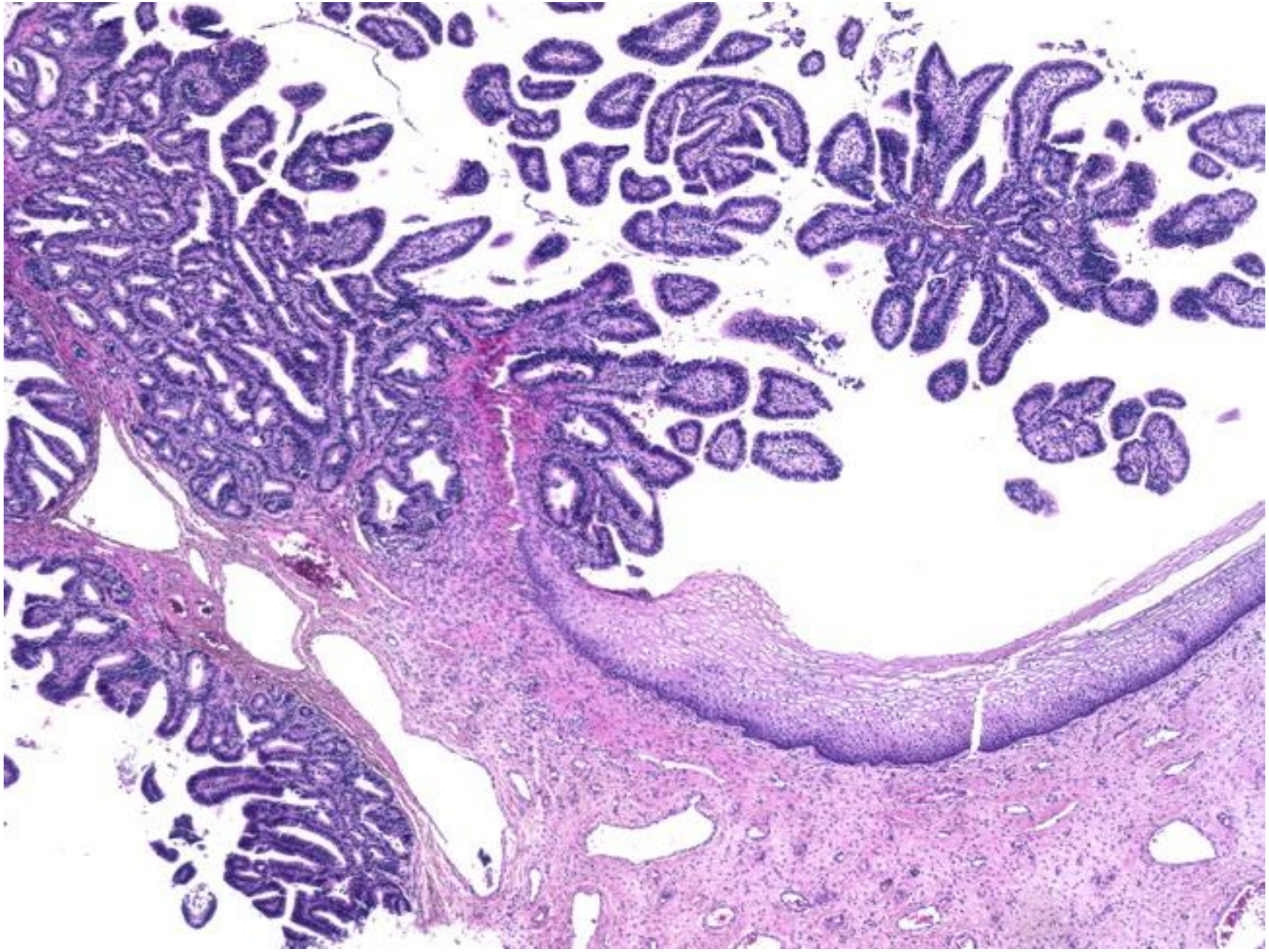

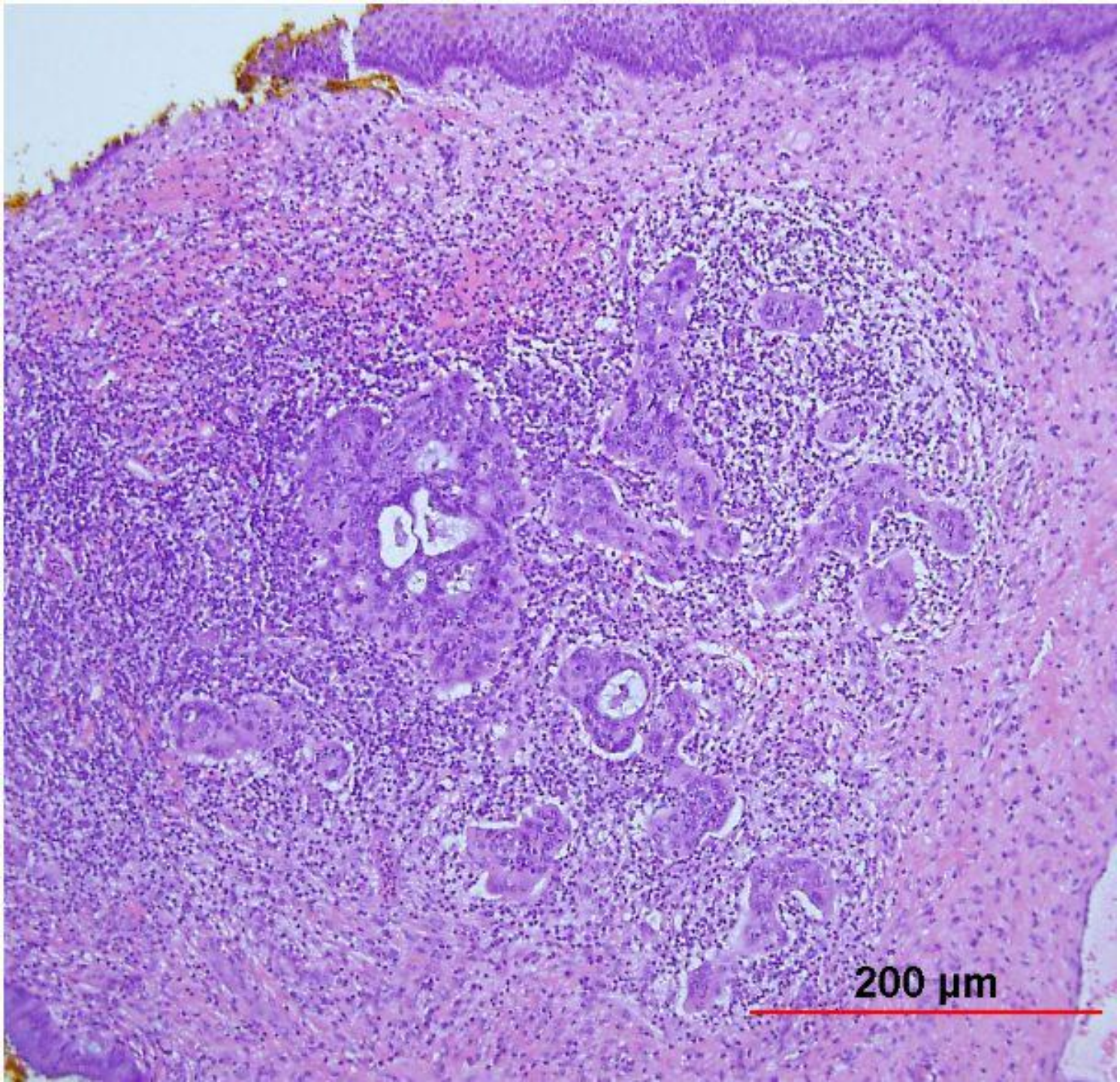
200 µm

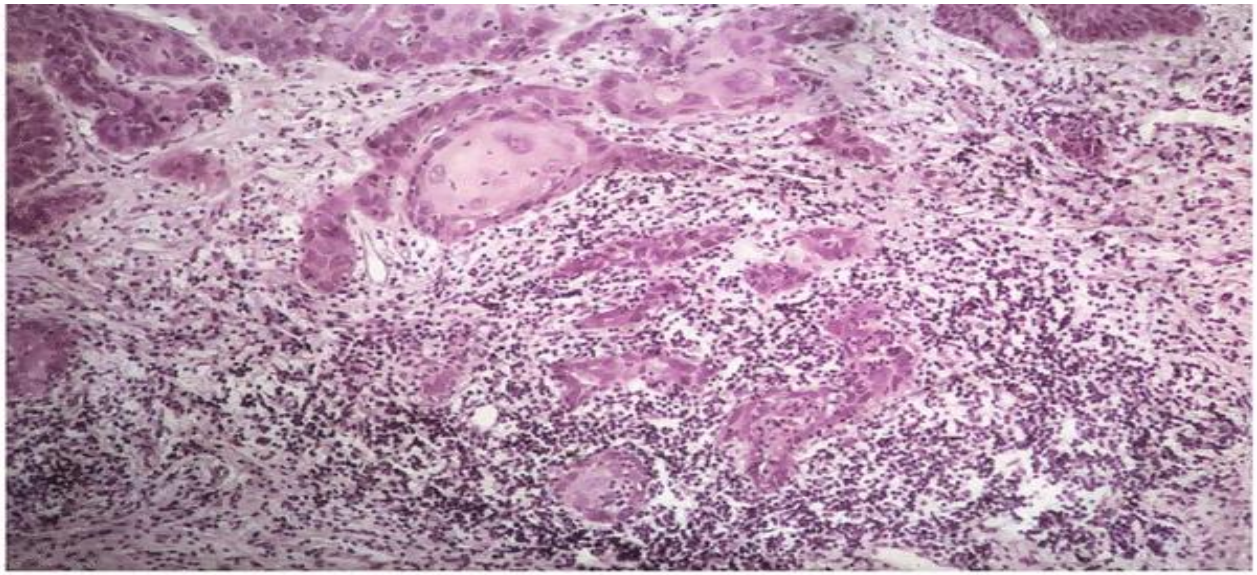

Fig. 150. Microinvasive carcinoma, netlike infiltration. H&E

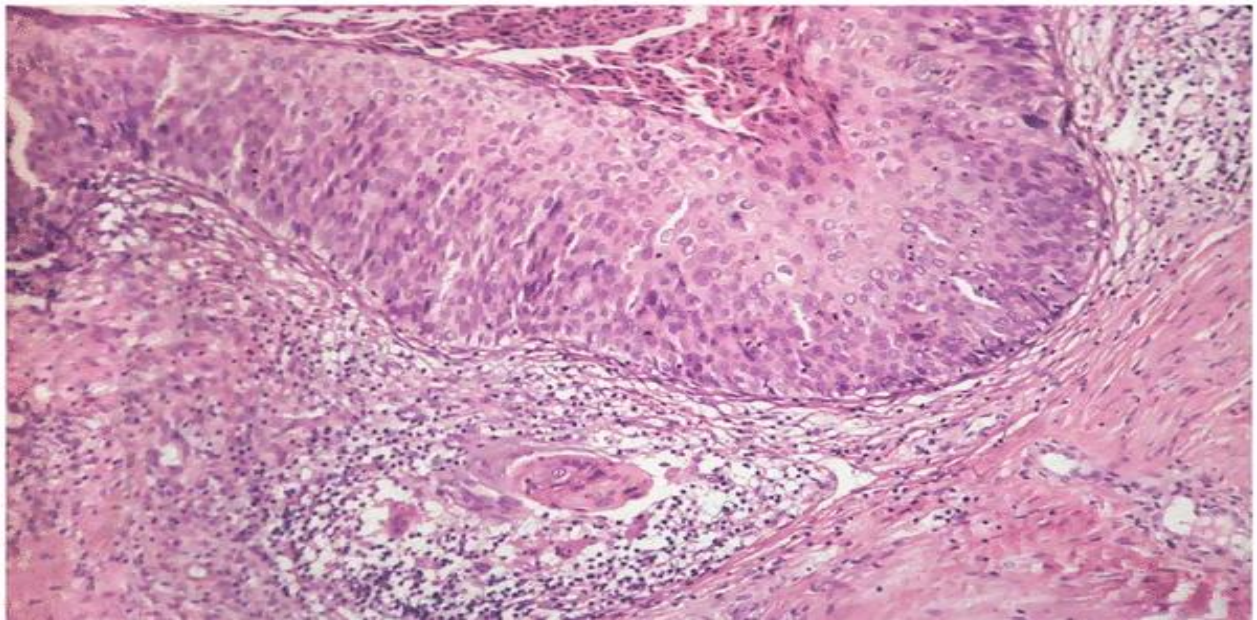

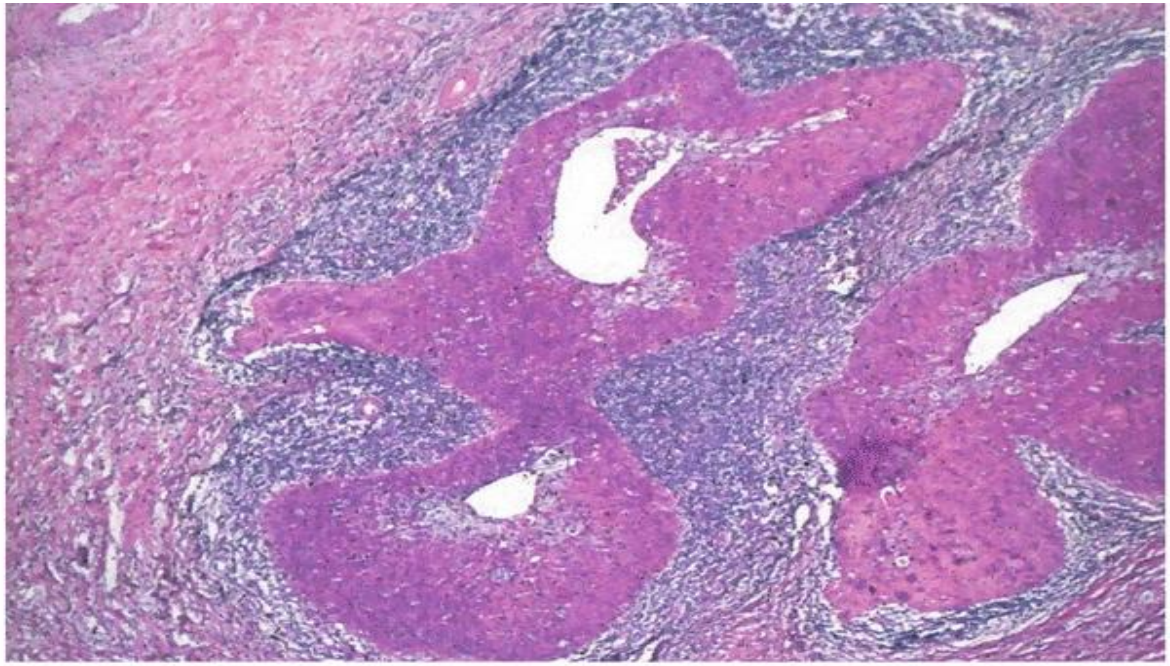

Fig. 156. Microinvasive carcinoma, extensive plump infiltration. H&E

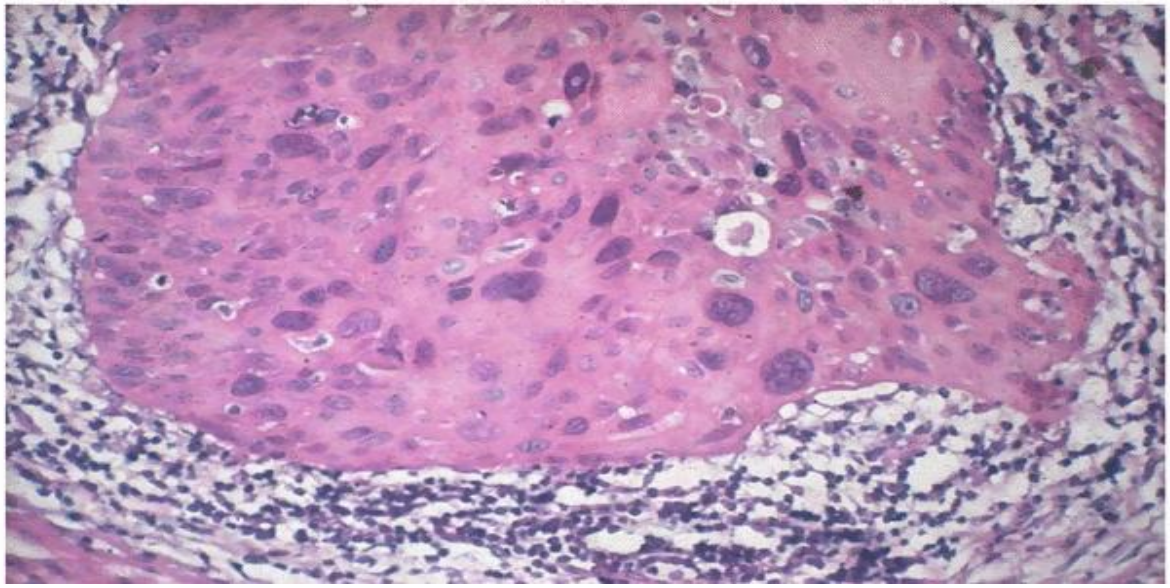

References

- W G McCluggage. Endocervical glandular lesions: controversial aspects and ancillary techniques. J. Clin. Pathol., Mar 2003; 56: 164 - 173.
- Young RH, Clement PB. Pseudoneoplastic glandular lesions of the uterine cervix. Semin Diagn Pathol. 1991 Nov;8(4):234-49.
- Awatif Al-Nafussi. Histopathological challenges in assessing invasion in squamous, glandular neoplasia of the cervix Current Diagnostic Pathology, Volume 12, Issue 5, October 2006, Pages 364-393